



# Osstem Implant System

## Documentations **Vol.6**



#### **HEAD OFFICE**

8th Fl, WorldMeridian Venture Center II, 426-5,  
Gasan-dong, Geumcheon-gu, Seoul, Korea  
Tel. 82-2-2016-7000 Fax. 82-2-2016-7001

#### **Implant R&D Center**

#38-44, Geoje 3-dong, Yeonje-gu, Busan, Korea. Zip. 611-801  
Tel. 82-70-7016-4745 Fax. 82-70-4394-0404  
project@osstem.com <http://www.osstem.com>

# Osstem Implant System

Documentations **Vol.6**

**OSSTEM**<sup>®</sup>  
IMPLANT

# Contents

## TS SYSTEM

Selected literature of published Journals

### ■ Clinical Study

Subjective Satisfaction of Clinician and Short-Term Clinical Evaluation of Osstem TSIII SA Implant ..... 10 J Korean Clinical Implant 2010;30(7):430-43	10
Case Report of Guided Bone Regeneration in Dehiscence-Type Defects Using Hydrophilic Surfaced Implant (TSIII CA) and SMARTbuilder ..... 11 Scientific Poster, Osstem Meeting 2013	11
Preliminary Clinical Evaluation of Customized Three-Dimensional Pre-formed Titanium Mesh for Localized Alveolar Bone Regeneration ..... 12 Scientific Poster, Osstem Meeting 2013	12
Preliminary Study for Hydraulic Sinus Membrane Elevation by CAS KIT without Bone Graft ..... 13 Scientific Poster, Osstem Meeting 2013	13
Prospective Comparative Study of Tapered Implant with SLA Surface at Maxillary Posterior Area According to Loading Time: 3 and 6 months ..... 14 Scientific Poster, 21st Congress of EAO 2012	14
Sinus Bone Grafting with Simultaneous Implant Placement in Case of Residual Bone Height Less Than 4mm Using TSIII SA Implant ..... 15 Scientific Poster, 22nd Congress of EAO 2013	15
A Case of Rehabilitation of Oral Function with Dental Implants Following Panfacial Bone Fracture ..... 16 Scientific Poster, Osstem Meeting 2013	16
Full Mouth Rehabilitation Utilizing the CAD/CAM Technology : Surgical Guide for Flapless Surgery, Provisional Restoration and Screw-Retained Fixed Complete Denture ..... 17 Scientific Poster, 21st Congress of EAO 2012	17
An Implant-Supported Restoration of a Maxillary Central Incisor Using a Temporary Abutment and a Customized CAD/CAM Titanium Abutment ..... 18 Scientific Poster, 21st Congress of EAO 2012	18
SmartFit Abutment and Custom Healing Abutment ..... 19 Scientific Poster, 21st Congress of EAO 2012	19
Clinical Comparative Study of Immediate Loading Using Tapered Implant with Hydroxyapatite Coating at the Partial Edentulous Ridge of Posterior Maxilla and Mandible ..... 20 Scientific Poster, 21st Congress of EAO 2012	20

### ■ Pre-Clinical Study

Effect of Microthreads on Removal Torque and Bone-to-Implant Contact: an Experimental Study in Miniature Pigs ..... 21 J Periodontal Implant Sci 2013;43:41-6	21
Enhancement of in Vitro Osteogenesis to Chemically Activated CA Surface Compared with SA Surface ..... 22 Scientific Poster, Osstem Meeting 2013	22
Effect of Photodynamic Therapy on Aggregatibacter Actinomycetemcomitans Attached on Titanium Surfaces ..... 23 Scientific Poster, Osstem Meeting 2013	23
Evaluation of Biomechanical Effect on Chemically Modified CA Surface in Vivo ..... 24 Scientific Poster, 21st Congress of EAO 2012	24
Biomechanical and Histomorphometrical Evaluation of Bone-Implant Integration at Sand Blasting with Alumina and Acid Etching (SA) Surface ..... 25 Scientific Poster, 19th Congress of EAO 2010	25
Experimental Study of Bone Response to Hydroxyapatite Coating Implants: BIC and Removal Torque Test ..... 26 Oral Surg Oral Med Oral Pathol Oral Radiol 2012;114(4):411-8	26
Comparative Study on the Durability of Abutment Post According to Tightening Torque and Cantilever Volume ..... 27 Scientific Poster, Osstem Meeting 2013	27

■ References ..... 28	28
-----------------------	----

## GS SYSTEM

Selected literature of published Journals

### ■ Clinical Study

A Multicenter Prospective Study in Type IV Bone of a Single Type of Implant Implant Dent. 2012 Aug;21(4):330-4	30
Comparison of Clinical Outcomes of Sinus Bone Graft with Simultaneous Implant Placement: 4-Month and 6-Month Final Prosthetic Loading Oral Surg Oral Med Oral Pathol Oral Radiol Endod. 2011 Feb;111(2):164-9	31
Prospective Study of Tapered RBM Surface Implant Stability in the Maxillary Posterior Area Oral Surg Oral Med Oral Pathol Oral Radiol. 2012 Jul;114(1):e19-24	32
A 1-Year Prospective Clinical Study of Soft Tissue Conditions and Marginal Bone Changes Around Dental Implants After Flapless Implant Surgery Oral Surg Oral Med Oral Pathol Oral Radiol Endod. 2011 Jan;111(1):41-6	33
A Relaxed Implant Bed: Implants Placed After Two Weeks of Osteotomy with Immediate Loading: A One Year Clinical Trial J Oral Implantol. 2012 Apr;38(2):155-64	34
Evaluation of Sinus Bone Resorption and Marginal Bone Loss After Sinus Bone Grafting and Implant Placement Oral Surg Oral Med Oral Pathol Oral Radiol Endod 2009;107:e21-8	35
Evaluation of Peri-implant Tissue Response According to the Presence of Keratinized Mucosa Oral Surg Oral Med Oral Pathol Oral Radiol Endod 2009;107:e24-8	36

### ■ Pre-Clinical Study

Morphogenesis of the Peri-Implant Mucosa: A Comparison Between Flap and Flapless Procedures in the Canine Mandible Oral Surg Oral Med Oral Pathol Oral Radiol Endod 2009;107:66-70	37
Influence of Premature Exposure of Implants on Early Crestal Bone Loss: An Experimental Study in Dogs Oral Surg Oral Med Oral Pathol Oral Radiol Endod 2008;105:702-6	38
Microleakage of Different Sealing Materials in Access Holes of Internal Connection Implant Systems J Prosthet Dent 2012;108:173-180	39
Fatigue Characteristics of Five Types of Implant-Abutment Joint Designs Met Master Int 2008;14(2):133-8	40
The Effect of Various Thread Designs on the Initial Stability of Taper Implants J Adv Prosthodont 2009;1:19-25	41

■ References	42
--------------	----

## SS SYSTEM

Selected literature of published Journals

### ■ Clinical Study

A Comparison of Implant Stability Quotients Measured Using Magnetic Resonance Frequency Analysis from Two Directions: Prospective Clinical Study During the Initial Healing Period Clin Oral Impl Res 2010;21(6):591-7	46
Non-Submerged Type Implant Stability Analysis During Initial Healing Period by Resonance Frequency Analysis J Korean Acad Periodontol 2009;39(3):339-48	47
Evaluation of Peri-Implant Tissue in Nonsubmerged Dental Implants: A Multicenter Retrospective Study Oral Surg Oral Med Oral Pathol Oral Radiol Endod 2009;108(2):189-95	48
A Randomized Clinical 1-year Trial Comparing Two Types of Non-Submerged Dental Implant Clin Oral Implants Res 2010 Feb;21(2):228-36	49
Four-Year Survival Rate of RBM Surface Internal Connection Non-Submerged Implants and the Change of the Peri-Implant Crestal Bone J Korean Assoc Maxillofac Plast Reconstr Surg 2009;31(3):237-42	50

### ■ Pre-Clinical Study

Influence of Abutment Connections and Plaque Control on the Initial Healing of Prematurely Exposed Implants: An Experimental Study in Dogs J Periodontol 2008;79(6):1070-4	51
Peri-Implant Bone Reactions at Delayed and Immediately Loaded Implants: An Experimental Study Oral Surg Oral Med Oral Pathol Oral Radiol Endod 2008;105:144-8	52
Flapless Implant Surgery: An Experimental Study Oral Surg Oral Med Oral Pathol Oral Radiol Endod 2007;104:24-8	53
The Effect of Internal Implant-Abutment Connection and Diameter on Screw Loosening J Kor Acad Prosthodont 2005;43(3):379-92	54

■ References	55
--------------	----

## US System

Selected literature of published Journals

### ■ Clinical Study

Success Rate and Marginal Bone Loss of Osstem USII Plus Implants: Short Term Clinical Study .....	58
J Korean Acad Prosthodont 2011;49(3):206-13	
The Study of Bone Density Assessment on Dental Implant Sites .....	59
J Korean Assoc Oral Maxillofac Surg 2010;36(5):417-22	
A Retrospective Evaluation of Implant Installation with Maxillary Sinus Augmentation by Lateral Window Technique .....	60
J Korean Assoc Maxillofac Plast Reconstr Surg 2008;30(5):457-64	
Multicenter Retrospective Clinical Study of Osstem USII Implant System in Type IV Bone .....	61
J Korean Implantology(KAOMI) 2007;11(3):22-9	
Multicenter Retrospective Clinical Study of Osstem USII Implant System in Complete Edentulous Patients .....	62
J Korean Implantology(KAOMI) 2007;11(3):12-21	
Retrospective Multicenter Cohort Study of the Clinical Performance of 2-Stage Implants in South Korean Populations .....	63
Int J Oral & Maxillof Implants 2006;21(5):785-8	

### ■ Pre-Clinical Study

The Effects of Surface Roughness on the Sandblasted with Large Grit Alumina and Acid Etched Surface Treatment: In Vivo Evaluation .....	64
Scientific Poster, 20th Congress of EAO 2011	
Effects of Different Depths of Gap on Healing of Surgically Created Coronal Defects Around Implants in Dogs: A Pilot Study .....	65
J Periodontol 2008;79(2):355-61	
The Effect of Surface Treatment of the Cervical Area of Implant on Bone Regeneration in Mini-Pig .....	66
J Korean Assoc Oral Maxillofac Surg 2008;34:285-92	
Comparison of Push-in Versus Pull-out Tests on Bone-Implant Interfaces of Rabbit Tibia Dental Implant Healing Model .....	67
Clin Implant Dent Res 2013;15(3):460-9	
Quantitative Biomechanical Analysis of the Influence of the Cortical Bone and Implant Length on Primary Stability .....	68
Clin Oral Impl Res 2013;23(10):1193-7	
Heat Transfer to the Implant-Bone Interface During Preparation of Zirconia/Alumina Complex Abutment .....	69
Int J Oral Maxillofac Implants 2009;24:679-83	
Fatigue Fracture of Different Dental Implant System Under Cyclic Loading .....	70
J Kor Acad Prosthodont 2009;47:424-34	

■ References .....	71
--------------------	----

## MS SYSTEM

Selected literature of published Journals

### ■ Clinical Study

Multicentric Retrospective Clinical Study on the Clinical Application of Mini Implant System .....	76
J Korean Assoc Oral Maxillofac Surg 2010;36(4):325-30	
Clinical Research of Immediate Restoration Implant with Mini-Implants in Edentulous Space .....	77
Hua Xi Kou Qiang Yi Xue Za Zhi 2010 Aug;28(4):412-6	

■ References .....	78
--------------------	----

# Subjective Satisfaction of Clinician and Short-Term Clinical Evaluation of Osstem TSIII SA Implant

Young-Kyun Kim, Ji-Hyun Bae  
J Korean Clinical Implant 2010;30(7):430-43

## Objective

Recently Osstem implant released a new product line, TSIII SA, which is processed by sand blasting using alumina and acid-etching. This new implant features a tapered design, with an open thread equipped on top to minimize necrosis of the alveolar bone, while its helix cutting edge allows self-tapping and easy adjustment of the installation direction. The apex is designed to improve probing ability into the bone tissue, and fixing ability on the bottom. The manufacturer explains the benefits of the TSIII SA as follows:

- 1) Excellent initial stability after loading on bone of poor quality
- 2) Possibility of early or immediate loading
- 3) Short time required for the procedure
- 4) Easy adjustment of cutting ability and depth
- 5) Easy correction of the installation direction

Therefore, the authors investigated the clinical benefits of this brand-new implant by evaluating the subjective satisfaction of clinicians and the short-term clinical outcome after the installation of TSIII SA implants in 41 medical centers that are actively involved with dental implantation nationwide, and we are reporting the results.

## Materials & Methods

A total of 41 dental clinics took part in this study. 51% of the centers used the GS system from Osstem implant and 49% used implants from different manufacturers. In total, 522 TSIII implants were installed for three months from 31 August to November 2009. Maxillary and mandibular posterior regions were the most frequently implanted areas, and prosthodontic treatments were carried out 3 to 4 months after the installation regardless of the installation region. 262 cases were completed with prosthodontic treatment upon completion of the study with the recovery of the questionnaires.

The questionnaire consisted of the following questions. Users from 41 centers completed the questionnaire based on their combined experience of 522 implantations.

- (1) Bone quality Bone quality was classified into hard, normal, or soft bone according to the clinician's personal evaluation.
- (2) How easy was it to secure the initial fixation?
- (3) How effective was the cutting ability of the implant into the bone tissue?
- (4) Clinician's compliance with the implantation procedure
- (5) Failure of the implantation in the early stage and the bone's response
- (6) Overall satisfaction with TSIII and other opinions

## Results

In this study, the TSIII SA implant was used in settings with various degrees of bone quality, and the success rate of implantation in the early stage was as high as 99.6%. The TSIII SA implant also showed excellent bone response, and the treatment period - from installation to prosthetic loading - was shortened by an average of 3-4 months. No significant difference was observed in initial fixing force and self-tapping ability, which indicates that the TSIII SA implants are no different to tapered implants in terms of their functionality.

The compliance evaluation revealed that most of the clinicians do not follow the procedure as specified by the manufacturers. Notably, a relatively high percentage of clinicians did not use a cortical drill during normal bone implantation due to the change in the design of the TSIII system to a single thread type. However, the use of a cortical drill is recommended because torque installation can deviate from the proper range in many cases. When a tapered implant is installed without using countersinking or cortical drilling in a cortical bone, the chances of excess torque occurring are higher, which can result in alveolar bone absorption during the healing process.

It is notable that 50% of the clinicians answered that there is no difference between the TSIII SA and previously preferred products in the overall satisfaction survey, while 25% of clinicians responded that they would wait and see before actually purchasing it for clinical application. Though the TSIII SA implant showed better results in the stimulation of initial bone conduction and bone response, most clinicians stated that they do not perceive any significant difference between the TSIII SA and previous models in terms of the design; as such, a long-term clinical evaluation of its short history since its commercial release will be necessary.

## Conclusions

1. A total of 522 implants were installed, 99.6% (n=520/522) of which were successful. Most of the clinicians evaluated that the TSIII SA implants exhibited excellent bone response.
2. About 50% of the clinicians answered that there was no significant difference between the TSIII SA and previously preferred products in terms of self-tapping ability and initial fixation.
3. The average treatment period was 3.9 months for the maxillar, and 3.4 months for the mandibular, which suggests that the TSIII SA implants can shorten the treatment period.
4. Overall satisfaction with the TSIII SA was rather high, but approximately 50% of the clinicians answered that there was no difference in terms of the satisfaction they felt with the TSIII SA compared to previously preferred products.

# Case Report of Guided Bone Regeneration in Dehiscence-Type Defects Using Hydrophilic Surfaced Implant (TSIII CA) and SMARTbuilder

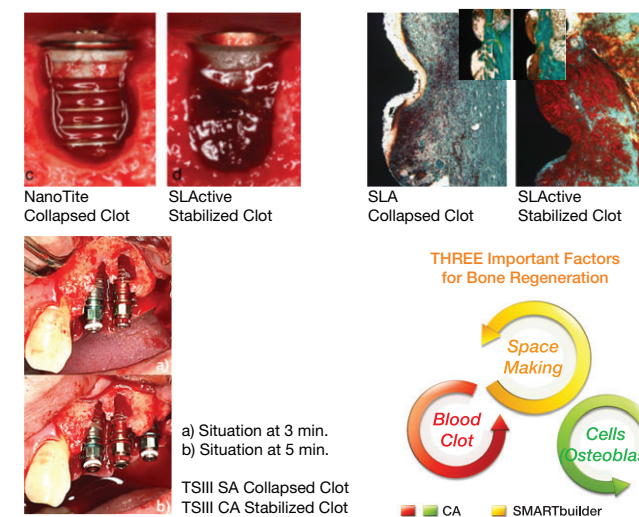
Yong-Jin Kim, Young-Jin Park, Kyung-Tae Park  
Scientific Poster, Osstem Meeting 2013

## Objective

Most recently, Osstem implant introduced a TSIII CA implant, a chemically modified sand-blasted, large grit and acid-etched titanium surface implant, in order to enhance bone apposition. It might be hypothesized that the hydrophilic properties of TSIII CA implant surfaces may have a higher potential to support osseointegration in dehiscence-type defects.

So, I would like to report the GBR case in dehiscence-type defects using hydrophilic surfaced implant (TSIII CA) and SMARTbuilder.

## Why hydrophilic surface in GBR ?



## Study design (Case Report)

- Age / Sex : 55Y / M • Chief complain : #34, 35, 36 Missing
- Past medical history : N / S
- Past dental history
  - #34 Extraction d / t chronic periodontitis 2 months ago
- Treatment plan
  - #34, 35, 36 implant placement
  - #34 GBR d / t buccal bone defect

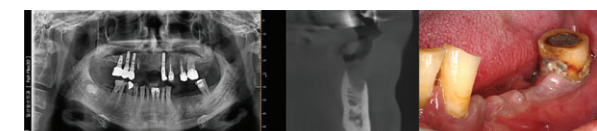


Fig. 1-3. Pre-operative radiograph & Intra-operative view

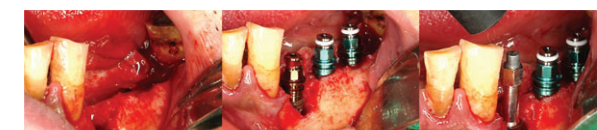

Fig. 4-6. Full thickness mucoperiosteal flap was elevated with crestral incision and one vertical incision on the buccal side of the residual alveolar ridge mesially. Buccal bone defect of #34 extraction socket was observed. TSIII CA implant 4.0x11.5mm was installed at #34 extraction socket. Insertion torque was 30NCm and ISQ value was 71.

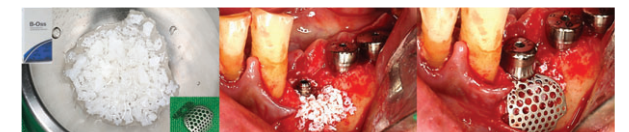

Fig. 7-9. B-Oss was soaked with normal saline and SMARTbuilder (2 wall augmentation) was trimmed with Iris scissors. B-Oss was grafted on the exposed TSIII CA implant and SMARTbuilder was placed. Healing abutment for SMARTbuilder was connected. The mucoperiosteal flap was closed using 4-0 Blue Nylon.

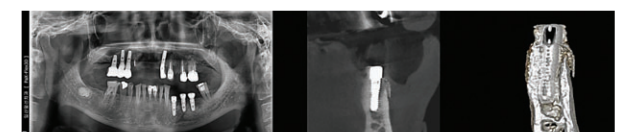


Fig. 10-12. Post-operative radiograph  
It was observed that bone graft material was well maintained under SMARTbuilder. In addition, the contour of bone graft was also well maintained because of the rigidity of SMARTbuilder.

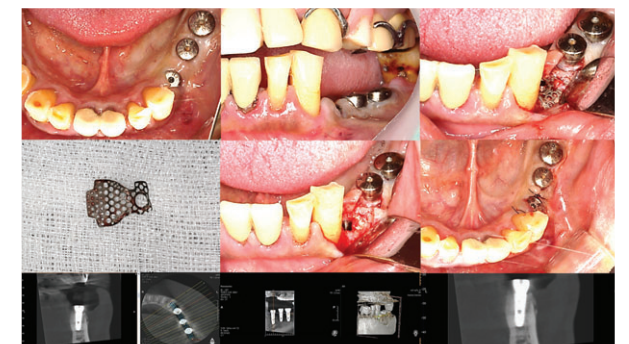


Fig. 13-21. 2nd-operative radiograph & Intra-operative view  
2nd stage surgery was done 14 weeks after implant placement. During the healing period, SMARTbuilder was not exposed. Mucoperiosteal flap was elevated with crestral incision and SMARTbuilder was removed. Bone regeneration around the TSIII CA implant was observed. Healing abutment (5x5mm) was connected and the mucoperiosteal flap was closed using 4-0 Blue Nylon.

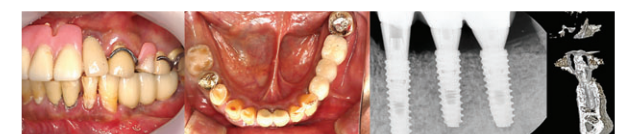

Fig. 22-24. Final prosthetic treatment was done 16 weeks after implant placement. Gingival condition around implants looks healthy.

## Conclusions

Three important factors for bone regeneration are space making, presence of blood clot and cells (osteoblasts). The hydrophilic properties of TSIII CA implant surfaces may play an important role in blood clot stabilization and cell (osteoblast) affinity. SMARTbuilder has excellent mechanical properties for stabilization of bone graft materials. Its rigidity prevents contour collapse, its elasticity prevents mucosa compression, and its stability prevents graft displacement. Thereby, an essential prerequisite for bone graft integration, ie, mechanical graft stability, could be guaranteed by SMARTbuilder.

So, it might be hypothesized that hydrophilic surfaced TSIII CA implant and SMARTbuilder are the best combination for successful bone regeneration in dehiscence-type defect

# Preliminary Clinical Evaluation of Customized Three-Dimensional Pre-formed Titanium Mesh for Localized Alveolar Bone Regeneration

Seung-Hwan Jeon, Kyung-Gyun Hwang, Chang-Joo Park  
Scientific Poster, Osstem Meeting 2013

## Objective

The purpose of this preliminary study is to evaluate the ability of customized three-dimensional titanium mesh (SMARTbuilder, Osstem, Korea) as a barrier membrane through investigation of clinical implant success rates and complications including crestal bone maintenance in application for localized alveolar bone regeneration.

## Materials & Methods

### 1. Patient selection

In a total of 8 patients, dental implants (TSIII CA, Osstem, Korea) were placed and SMARTbuilder, height, healing abutment or cover cap were applied for bone regeneration simultaneously (Table 1).

### 2. Surgical technique

Autogenous bone, which was harvested by Autobone Collector (Osstem, Korea) (Fig. 1) and mixed with allograft (Sure-Oss, HansBiomed co., Korea) 1 : 1 in volumetric ratio, was used as graft material (Fig. 2).

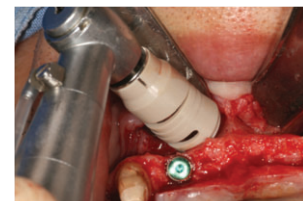


Fig. 1. Autogenous bone harvest

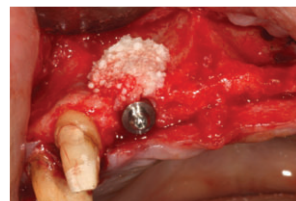

Fig. 2. Bone graft

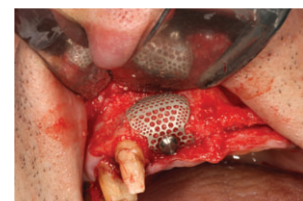

Fig. 3. Post operative periapical film

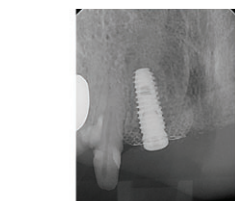

Fig. 4. SMARTbuilder

SMARTbuilder was applied as a barrier membrane (Fig. 3).

As seen on the Fig. 4, SMARTbuilder provided the space maintenance.

During healing period, SMARTbuilder cover cap was exposed (Fig. 5) and after 4 months from the operation, SMARTbuilder was removed (Fig. 6). New bone augmentation was achieved on the labial dehiscence (Fig. 7).

After uncovering operation, prosthetic procedure was performed. The complication and success rate were investigated until 6 months after the delivery of the definite prostheses.

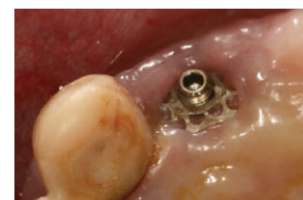

Fig. 5. Postoperative 4 months

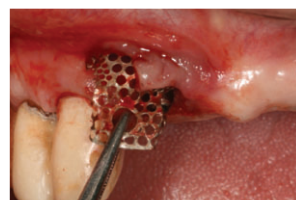

Fig. 6. Membrane removal at postoperative 4 months

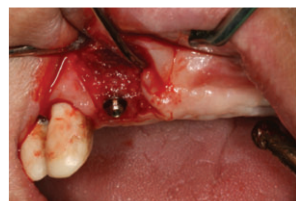

Fig. 7. Bone regeneration

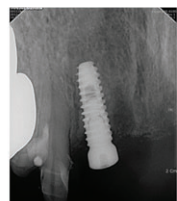

Fig. 8. Postoperative 4 months

## Results

Table 1. Overview of patients and surgical records

Patient number	sex	age	Surgical site	implant	SMART builder	Height	Cap / Healing	Complications*
1	M	39	#13	4.0X13	III 7X9X7	4X2	H	-
2	M	87	#46	4.5X10	II 10X12X7	4X1	C	+
3	M	59	#12	4.0X10	II 10X12X9	4X1	C	+
4	M	73	#15	4.0X11.5	III 10X12X7	4X2	H	-
5	F	64	#15	4.0X10	I 4X8X7	4X1	H	-
6	F	54	#45	4.5X8.5	II 10X12X9	4X2	C	+
7	F	17	#21	4.0X10	I 4X10X9	4X1	C	-
8	M	52	#16	4.5X8.5	III 10X12X9	4X2	H	-

\*Complications are cap exposure with wound dehiscence

## Discussion

Several benefits of the use of titanium mesh have been suggested. Titanium mesh provides superior space maintenance, a fundamental prerequisite for any bone regeneration procedure. Furthermore, the pores within the titanium mesh are thought to play a critical role in maintaining blood supply to a grafted defect.

Previous studies have suggested that a barrier membrane can exclude the ingress of blood supply to a grafted defect, resulting in flap dehiscence and membrane exposure. Furthermore, Expanded polytetrafluoroethylene (ePTFE) membranes must be removed if flap dehiscence and exposure occurs to prevent infection, because exposure in these cases will not heal spontaneously.

Titanium mesh, in contrast, when exposed, might not require immediate removal, because this material does not interfere with the blood flow to the underlying tissues owing to the presence of pores within the mesh. The size of these pores could be a significant factor because small pores could block the integral vascularization process. Another advantage of titanium mesh is that it provides the most extensive space maintenance of all available materials. This results from the great plasticity of the material, which permits bending, contouring, and adaptation of the mesh to any unique bony defect. The result is the establishment of a defined space below the mesh that mimics the shape of the desired alveolar ridge.

## Conclusions

SMARTbuilder showed the feasibility as the barrier membrane maximizing the merit of the existing titanium mesh, especially with the ease of application and removal during the augmentation procedures for localized alveolar bone defect.

# Preliminary Study for Hydraulic Sinus Membrane Elevation by CAS KIT without Bone Graft

Kun-Soo Chang, Kyung-gyun Hwang, Chang-Joo Park  
Scientific Poster, Osstem Meeting 2013

## Objective

The purpose of this preliminary study is to investigate the feasibility of no bone graft in maxillary sinus elevation during the implant treatment and to evaluate the amount of bone formation under a sinus membrane tented with implants and filled with saline or venous blood as a graft material in edentulous area of maxillary posterior. Instead of lateral approach, CAS KIT (Osstem, Korea), which is famous for hydraulic sinus membrane elevation via crestal approach, is utilized in this study.

## Materials & Methods

In a patient with the posterior maxillary edentulism, the placement of dental implants, hydraulic sinus membrane elevation via crestal approach by CAS KIT, and saline or venous blood filling for space maintenance were performed (Fig 1).

Their residual alveolar bone height (RBH) was over 5 mm and the length of dental implants was selected as near doubled RBH. Periapical and panoramic radiographs, including cone-beam computed tomography (CT), which were taken preoperatively (T0), and at postoperative 1 months (T1), 6 months (T2), and 12 months (T3), were used to evaluate the bone formation in the maxillary sinus floor.

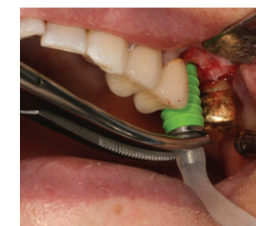


Fig. 1. Lift membrane using hydraulic lift system

## Results

The study population comprised 20 patients, 11 men and 9 women, ranging from 27 to 70 years in age (mean age, 45 years). Sinus lift procedures were performed by CAS KIT with implant placement simultaneously. Saline or venous blood filling for space maintenance were performed in each 10 cases. No significant complications were observed in any of the patients during the healing period, except for physiologic swelling after surgery. In a total 35 implants (TSIII CA, Osstem, Korea), 14 implants were inserted at premolar areas and 21 implants at molar areas. Of these implants, 3 were TSIII CA 4.0mm x 10mm, 7 were TSIII 4.0 x 11.5mm, 1 was TSIII 4.5mm x 8.5mm, 3 were TSIII 4.5mm x 10mm, 16 were 4.5 x 11.5mm, 1 was TSIII 5.0mm x 10mm, and 3 were 5.0mm x 10mm (Table 1).

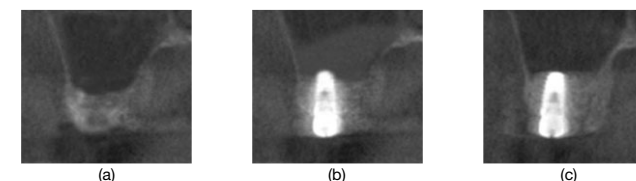


Fig. 2. Staged CBCT image (coronal view)  
(a) preoperative (T0), (b) immediate postoperative, (c) postoperative 12months (T3)

There were no signs or symptoms of infection or maxillary sinus disease. Thirty-five implants in lengths of 8.5 to 11.5 mm were placed, with an average RBH of 6.8 mm (range 5-9 mm). All the implants remained clinically stable during the study period. Comparison of pre- and postoperative radiographs clearly demonstrated bone formation within the compartment created by the sinus elevation procedure, however, slight drooping of the sinus membrane was observed in all the cases.

Table 1. Basic data for this prospective clinical study

Case number	Age (yr)	Sex (M/F)	Implant position	Residual bone height (mm)	Implant placed	Filling material*
1	54	M	#16	5.4	TSIII CA 4.5X10	S
			#17	5.3	TSIII CA 4.5X10	
2	60	F	#15	6.0	TSIII CA 4.5X11.5	V
			#25	7.1	TSIII CA 5.0X11.5	S
3	51	M	#26	7.4	TSIII CA 4.5X11.5	
			#27	7.3	TSIII CA 4.5X11.5	
4	29	M	#16	9.0	TSIII CA 4.5 X11.5	V
			#25	8.1	TSIII CA 4.5X11.5	V
5	70	F	#26	8.4	TSIII CA 4.5X11.5	S
			#14	5.4	TSIII CA 4.0X10	S
6	35	F	#15	5.5	TSIII CA 4.0X10	
			#27	8.0	TSIII CA 4.5X11.5	S
7	28	M	#17	8.5	TSIII CA 5.0X11.5	V
			#16	6.1	TSIII CA 4.5X11.5	S
8	50	F	#17	6.4	TSIII CA 4.5X11.5	S
			#24	7.8	TSIII CA 4.0X11.5	V
9	61	M	#25	7.9	TSIII CA 4.0X11.5	
			#26	8.0	TSIII CA 4.5X11.5	
10	35	F	#15	7.1	TSIII CA 4.0X11.5	S
			#16	7.4	TSIII CA 4.5X11.5	
11	33	M	#17	7.0	TSIII CA 4.5X11.5	
			#26	5.1	TSIII CA 5.0X10	S
12	27	M	#15	6.0	TSIII CA 4.0X11.5	S
			#16	6.3	TSIII CA 4.5X11.5	
13	59	F	#16	6.3	TSIII CA 4.5X11.5	
			#24	7.9	TSIII CA 4.0X11.5	V
14	61	F	#25	8.0	TSIII CA 4.0X11.5	
			#26	7.6	TSIII CA 4.5X11.5	
15	66	M	#27	5.9	TSIII CA 5.0X11.5	V
			#15	5.5	TSIII CA 4.0X10	V
16	29	F	#16	5.5	TSIII CA 4.5X10	
			#17	6.0	TSIII CA 4.5X11.5	
17	36	F	#27	6.3	TSIII CA 4.5X11.5	V
			#24	6.9	TSIII CA 4.0X11.5	V
18	41	M	#25	5.0	TSIII CA 4.5X8.5	S
			#26	5.2	TSIII CA 4.5X10	
19	47	M	#25	5.2	TSIII CA 4.5X10	
			#26	5.2	TSIII CA 4.5X10	
20	39	M	#25	5.0	TSIII CA 4.5X8.5	S
			#26	5.2	TSIII CA 4.5X10	

45.6 ± 14.0 6.8 ± 1.2

\*S; saline, V; patient's venous blood

Table 2. Measurement of average residual alveolar bone height (RBH)

	Alveolar bone height (n=35)	Gain of alveolar bone height (mm)
T0	6.8 ± 1.2	
Immediate PostOP	14.1 ± 2.5	7.2 ± 1.8*
T1	11.9 ± 2.9	5.1 ± 2.2*
T2	10.0 ± 1.8	3.1 ± 1.6†
T3	8.9 ± 2.1	2.0 ± 1.9†

Mean ± S.D. \*significant difference at P < 0.05, † significant difference at P < 0.01

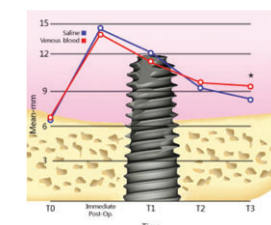


Fig. 3. Schematic drawing showing the measurement of intra-sinus newly formed bone level in the maxillary sinus as measured in CBCT over time  
(\*significant difference at P < 0.05)

## Conclusions

Maxillary sinus membrane elevation with the simultaneous placement of implants without the use of any additional grafting material resulted in intra sinus hard tissue formation around the implants for a follow-up period of up to 12 months. According to our observations, filling of peripheral venous blood instead of a graft material can be a more viable alternative to bone substitutes and safely used in maxillary sinus augmentation than filling of saline. New bone formation was verified by the stabilization of the elevated sinus membrane from the tenting effect of placement of dental implants and clots of venous blood without bone graft material. Our preliminary study shows that successful bone formation in the sinus floor by hydraulic sinus membrane elevation using CAS KIT without bone graft.

# Prospective Comparative Study of Tapered Implant with SLA Surface at Maxillary Posterior Area According to Loading Time: 3 and 6 months

Kyo-Jin Ahn, Young-Kyun Kim  
Scientific Poster, 21st Congress of EAO 2012

## Objective

The aim of this study was to evaluate prospective clinical results of tapered implants with SLA surface which was installed at maxillary posterior area and loaded 3 months after implant placement.

## Materials & Methods

- Subjects**
  - From November 2009 through September 2010
  - Implant: TSIII SA (Osstem, Seoul, Korea)
  - Site: Posterior area, Maxilla
  - Group classification: Loading time
    - Test group (3m): 3 months after placement
    - Control group (6m): 6 months after placement

## Subject Information

	Test group	Gain of alveolar bone height (mm)
Patient	18	18
Age	56.5 ± 11.9	61.7 ± 11.2
Implant	35	33
Follow up span	15.17 ± 5.4	14.48 ± 2.7

- Methods**
  - Hard tissue evaluation:**
    - Periapical view (6 months, 12 months after loading)
    - Stability : ISQ (Osstell mentor)
  - Soft tissue evaluation:**
    - AG (attached gingiva)
    - PI (Plaque index)
    - GI (Gingival index)
    - PD (Pocket depth): Buccal (B), Mesial (M), Distal (D), Palatal (P)
  - Prosthetic evaluation**
    - Crown - Implant ration (C/I ratio)
    - Opposite occlusal arch status
    - Occlusal gap: Controlled by Shimstock (8 μm) and Acufilm (27 μm) articulating paper

## Results

### 1. Additional Surgical Process

	Flapless	GBR	Sinus lift	Sinus lift with GBR	Ridge splitting
3m	5	8	6	10	0
6m	7	6	6	5	1

### 2. Hard Tissue Evaluation

	6 months loaded	12 months loaded
3m	0.2±0.4 mm	0.2±0.3 mm
6m	0.1±0.2 mm	0.2±0.3 mm

### 2-2. Stability (ISQ)

	First Operation	Second Operation
3m	69.7±8.7	74.3±6.0
6m	67.1±9.9	72.3±6.7

### 3. Soft Tissue Evaluation

	AG	PI	GI	PO			
				B	M	D	P
3m	2.1	0.8	0.6	2.7	2.6	2.9	2.5
6m	2.8	0.9	0.5	2.9	3.5	3.1	3.1

### 4. Prosthetic Evaluation

	Natural teeth	Implant	Occlusal gap(μ)
3m	23	12	9.1±9.3
6m	28	5	3.2±5.4

### 4-2. Prosthetic type

	Single Prosthetic	Splinted Prosthetics
3m	4	31
6m	5	28

### 4-3. Crown to Implant ratio

3m	6m
1	1.1

### 5. Success rate

3m	6m
1	1.1

## Conclusions

Within this limitation of short-term evaluation, we achieved favorable clinical results as follows that tapered implants with SLA surface can be used as which is placed at maxillary posterior area and followed 3-months loading protocol.

# Sinus Bone Grafting with Simultaneous Implant Placement in Case of Residual Bone Height Less Than 4mm Using TSIII SA Implant

Yong-Jin Kim, Young-Jin Park, Kyung-Tae Park  
Scientific Poster, 22nd Congress of EAO 2013

## Objective

Sinus bone grafting and implant placement are predictable treatment options for pneumatized maxillary sinus and severely resorbed maxillary posterior reconstruction. A minimum of 4~5 mm of residual bone height is traditionally recommended for the one-stage surgical procedure of sinus bone grafting and implant placement to ensure initial stability from preexisting residual bone. I would like to report the survival rates of the TSIII SA implants simultaneously placed into grafted maxillary sinus where the residual alveolar bone height was less than 4mm.

## Materials & Methods

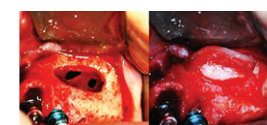
- From Jan. 2010 through Sep. 2012
- Average follow-up: 15.8±7.1 months after the implant placement (Min. 188 day~Max. 1,003 day)
- Implant / Bone graft material: TSIII SA / OssteOss
- Site: Posterior maxillary bone deficiency  
Residual alveolar bone height 1~4 mm
- Medical History: Those with controlled medical conditions

Table 1. Patient & Implant Information

	Male	Female	SUM
Patient	48	32	80
Age	54.6 ± 8.4	59.0 ± 11.1	55.7±9.7 (29y~79y)
Implant	110	58	168

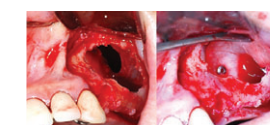
## Perforation management

- Perforation size<5mm



Bovine collagen membrane (Lyoplast®, B.Braun Surgical GmbH, Germany) was used.

Perforation size>5mm



Bovine collagen membrane (Lyoplast®, B.Braun Surgical GmbH, Germany) was fixed to sinus medial wall with titanium pin (TruTACK®, ACE Surgical Supply, USA) to obtain membrane security.

## Time Schedule for Second Surgery and Prosthodontic Treatment

2nd stage surgery was performed about 5.57 months (Min. 112 ~ Max. 409 day) after implant placement. Marginal bone level, implant mobility, and presence of fistula were examined. Final impression was taken 1 or 2 weeks after 2nd stage surgery. In other words, final prosthetic performed about 6.23 months (Min. 139 ~ Max. 423 day) after implant placement. All patients were treated with a fixed implant-supported prosthesis for final restoration. The final tightening torque of abutment was 30Ncm. The screw-retained porcelain fused metal or gold crown was fabricated for definitive restorations.

## Results

Table 2. Systemic disease, 80 patients 20 (25%)

Controlled DM	HTN	Rheumatoid and depression	Prostatic hypertrophy and hyperlipidemia
6	14	1	1

Table 3. Smoking status, 80 patients 16 (20%)

1/2~1 Pack	1~2 Pack	2 Pack~
8	7	1

Table 4. Site distribution

Diameter	4.0	4.5	5.0	6.0	7.0	SUM
Length	11.5					
#14	1	-	-	-	-	1
#15	4	4	1	1	-	10
#16	-	12	21	5	1	39
#17	-	6	16	7	1	30
#24	2	-	-	-	-	2
#25	4	4	-	2	-	10
#26	-	13	28	4	-	45
#27	-	5	22	4	-	31
SUM	11	44	88	23	2	168

Table 5. Residual alveolar bone height (mm)

0~1mm	1~2mm	2~3mm	3~4mm
12 (7%)	46 (28%)	61 (37%)	47 (28%)

Table 6. Implantation types / Bone Density

Non-Submerged	Submerged	Normal	Soft
13 (8%)	155 (92%)	124 (74%)	44 (26%)

Table 7. Insertion Torque

~10Ncm	11~20Ncm	21~30Ncm	30~40Ncm
17(10%)	59 (35%)	83 (49%)	9 (6%)

Table 8. Placement of site conditions (Perforations)

Good	Incomplete healing	Immediate Extraction
124 (10, 8%)	34 (10, 29.4%)	10 (4, 25%)

Table 9. Sinus membrane perforations during the operation  
80 patients 10 (12.5%) / 168 sites 24 (14.2%)

< 5mm	> 5mm
8 patients 20 sites	2 patients 4 sites

Table 10. Cumulative survival rates (Mean F/up 15.8±7.1months)

Survival	Fail
167 (99.4%)	1 (0.6%)

## Conclusions

Sinus bone grafting with simultaneous implant placement can be used to treat the atrophic maxilla in patients irrespective of residual bone when careful surgical methods and taper designed implants are used. Immediate sinus bone grafting with simultaneous implant placement can reduce the number of surgeries and overall treatment time. Membrane perforation did not have an adverse effect on implant success if the membrane was properly repaired. In this study, even a short period of time, but the cumulative survival rates were 99.4% with an average follow-up of 15.8±7.1 months. So, it is concluded that sinus bone grafting with simultaneous implant placement in case of residual bone height less than 4mm could be considered as a predictable procedure.



# A Case of Rehabilitation of Oral Function with Dental Implants Following Panfacial Bone Fracture

Hyung-Sik Do, Young-Il Song, Hwan-Yong Jang, Jin-Yong Lee, Jae-Hyung Lim, Hyun-Seok Jang, Jong-Jin Kwon, Jae-Suk Rim, Eui-Seok Lee  
Scientific Poster, Osstem Meeting 2013

## Objective

Panfacial fractures involve trauma to mandibular and maxillary bones. It requires a team approach for management and planned treatment plan. A functional and esthetic rehabilitation was successfully accomplished by using a partial removable dental prosthesis in the maxilla and Ramus block bone and allogenic bone graft with dental implants to support fixed dental prosthesis in the mandible.

## Study design (Case Report)

1. Sex/Age : Male/31
2. C.C : Panfacial fracture  
Missing teeth due to trauma
3. Clinical history : Patient was involved in a motor-cycle collision on september 9, 2011, and pelvic bone fracture, malar and maxillary bones fracture, mandibular symphysis fracture, laceration on tongue and chin. He also had laceration on right nasolabial fold, loss of several teeth, alveolar bone fracture.
4. Missing teeth : #11, 21, 22, 34, 33, 32, 31, 41, 42, 43
5. Treatment plan : Open reduction and internal fixation on fracture site. To get a sufficient depth of bone for the dental implants, we decided to use ramus block bone and allogenic bone graft on maxilla and mandible. We plan to use a partial removable denture for the maxilla and insert the Osstem TS system implants in the mandible.
6. Treatment process

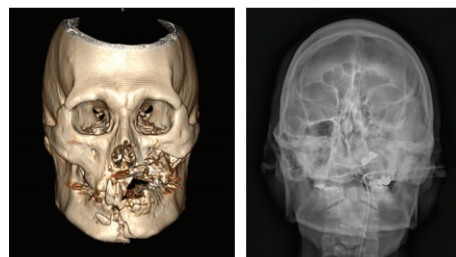


Fig.1. Three-dimensional CT and Skull x-ray photo showing panfacial fracture. Maxilla and mandibular teeth were missing.

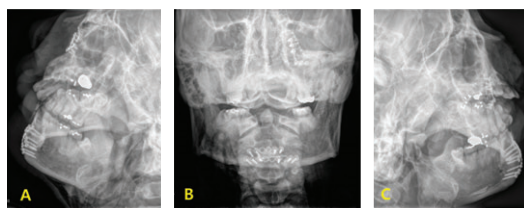


Fig.2. Postoperative Skull x-ray photo showing open reduction and internal fixation on panfacial fracture.  
a) Rt. lateral oblique mandibular x-ray photo b) Mandibular PA view x-ray photo  
c) Lt. lateral oblique mandibular x-ray photo

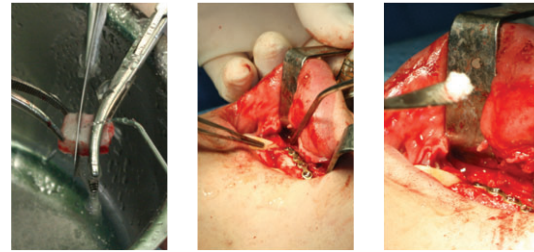


Fig.3. Ramus block bone graft and allogenic bone graft on maxilla and mandible.

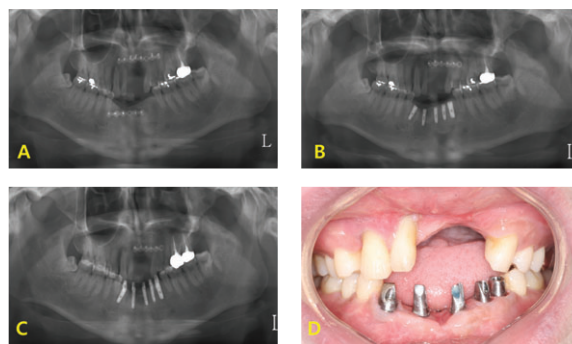


Fig.4. A) Panoramic radiograph of block bone graft  
B) Panoramic radiograph of dental implants after placement  
C) Panoramic radiograph of dental implants with custom abutment  
D) Intraoral view of dental implants with custom abutment

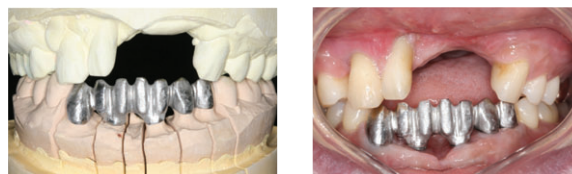

Fig.5. Metal framework for mandibular implant supported restoration

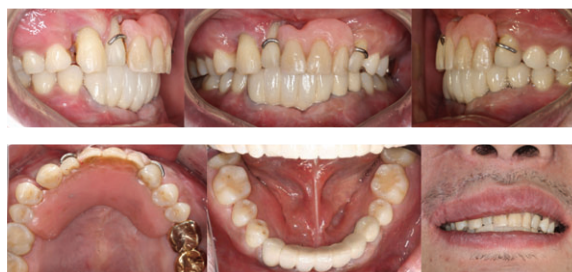

Fig.6. Intraoral view and Extraoral view photo

## Conclusions

This clinical report describes the prosthodontics treatment after the open reduction of a panfacial fracture. After the operation of such complex traumas, the locations of the fractured segments and the occlusion are distorted and present a challenge to us, resulting in problems such as facial deformation, inefficient mastication, and mal-function of the TMJ. In 2013, restoration was completed with final prosthodontics. In upper jaw, we treated the patient with removable partial denture because of the alveolar bone and tissue deficiency.

# Full Mouth Rehabilitation Utilizing the CAD/CAM Technology : Surgical Guide for Flapless Surgery, Provisional Restoration and Screw-Retained Fixed Complete Denture

Choon-Mo Yang  
Scientific Poster, 21st Congress of EAO 2012

## Objective

The ideal treatment planning, accurate placement, and functional restoration of dental implants for the completely edentulous patient can be challenging. Anatomical limitations can make implant location difficult to determine. The use of CT scans and surgical planning software to produce a CAD/CAM surgical guide, as well as the use of a flapless surgical technique, can make implant placement more predictable, safer, and easier for patients. Furthermore, CAD/CAM-guided fabrication of an provisional restoration and screw-retained definite prosthesis can result in predictable and successful full mouth reconstruction.

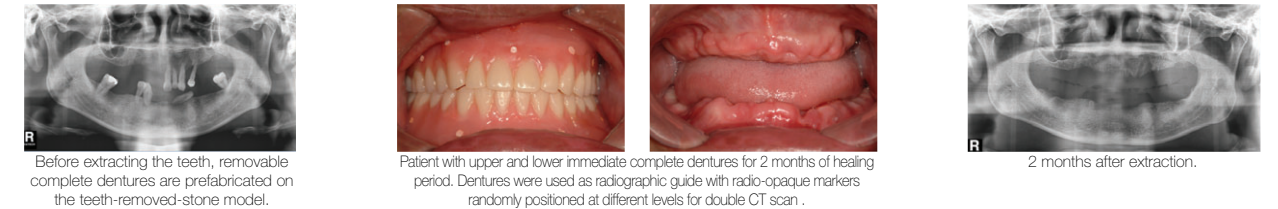
## Study design (Case Report)

- Immediate Removable Complete Denture
- CAD/CAM Surgical Guide: OsstemGuide
- CAD/CAM Provisional restoration
- Convertible Abutment, Lateral fixation screw
- CAD/CAM full Zirconia prosthesis

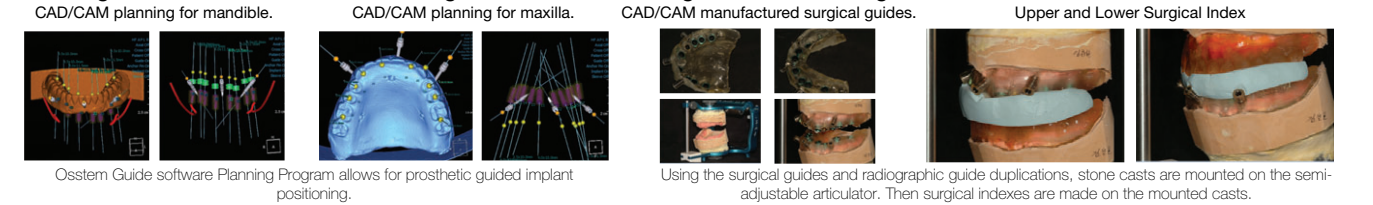
## Conclusions

The advantages of this procedure, for the completely edentulous arch, include (1) shorter surgery times, (2) shorter treatment times, (3) less invasive, flapless surgery and, therefore, less chance of swelling, less pain, and faster healing

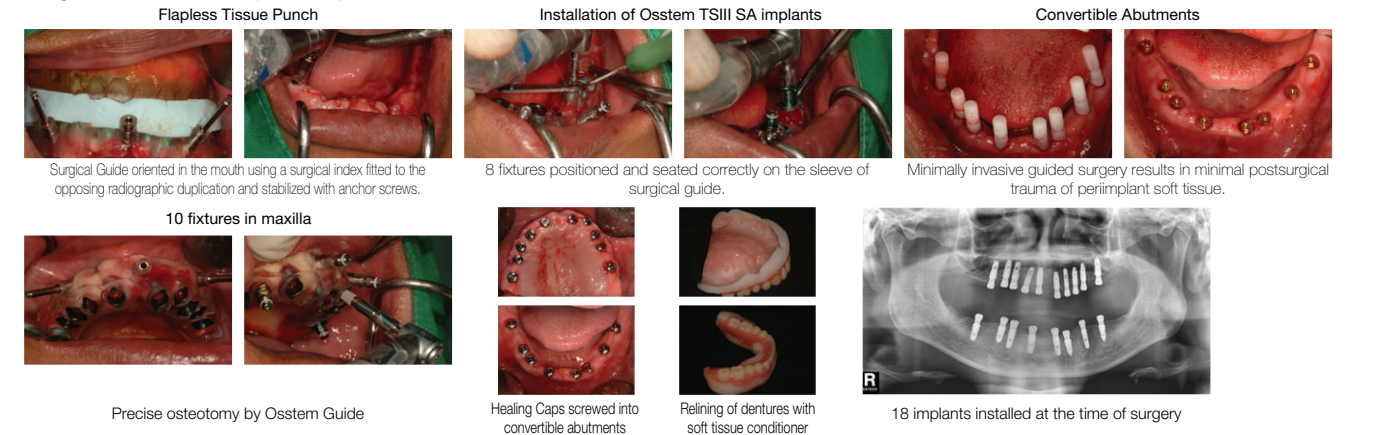
## Pre-surgical Procedure: Extraction and Immediate Removable Complete Denture



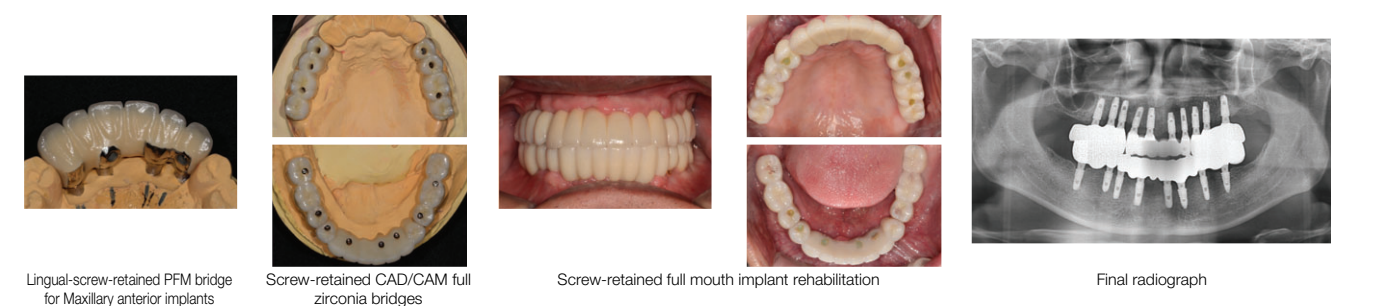
## Pre-surgical Procedure: CAD/CAM Planning and Fabrication of Surgical Guide and Surgical Index



## Surgical Procedure: Flapless Implantation



## Prosthetic Procedure : CAD/CAM Provisional Restoration



# An Implant-Supported Restoration of a Maxillary Central Incisor Using a Temporary Abutment and a Customized CAD/CAM Titanium Abutment

Hwee-Woong Park  
Scientific Poster, 21st Congress of EAO 2012

## Objective

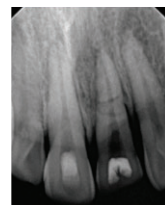
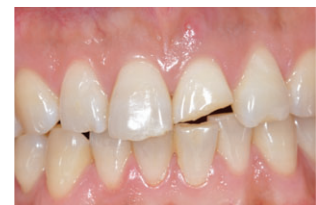Maxillary central incisors play a critical role in esthetics. One of the most difficult factors for an esthetic implant restoration is the natural profile of the cervical area in which the tooth emerges from inside the gingiva. Many procedures including bone augmentation and soft tissue graft have been suggested to solve this problem.

More recently, techniques using CAD/CAM customized abutments are drawing attentions as promising solutions.

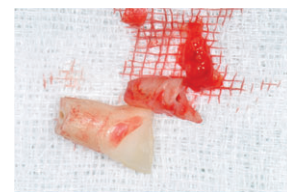
The author describes a clinical case with a missing upper central tooth restored using an Osstem TS Implant and a customized CAD/CAM (Osstem SmartFit) abutment.

## Study design (Case Report)

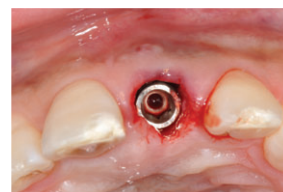- Patient age/sex: 28Y, male
- C/C: Teeth fracture due to trauma
- Clinical findings
  - Crown fracture of maxillary anterior teeth
  - Root fracture of Lt. central incisor
  - Apical radiolucency and fistula



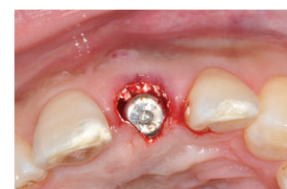- Surgery
  - #21 tooth was extracted with minimal trauma and the granulation tissue was removed.
  - After careful drilling, a TSIII SA implant (4.0X13mm) was installed.
  - Insertion torque was 25Ncm.
  - The gap between the implant and the labial alveolar plate was filled with synthetic bone graft material (biphasic calcium phosphate).
  - A short healing abutment was connected and a bonded temporary restoration was placed.



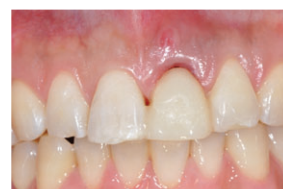Extraction and curettage



Implant placement



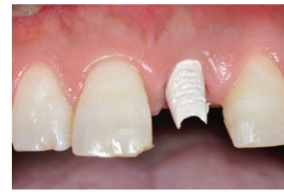Gap filling with synthetic bone



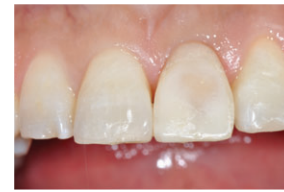Temporary restoration

## • Provisional Restoration

A provisional restoration supported by a temporary abutment was placed 10 weeks after implant placement.



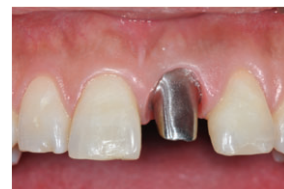
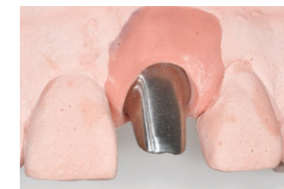Temporary abutment



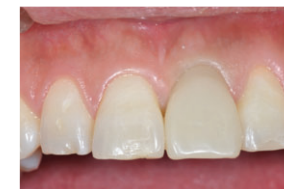Provisional restoration

## • CAD/CAM Abutment

A SmartFit abutment was fabricated with a fixture-level impression and a cast.



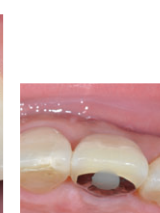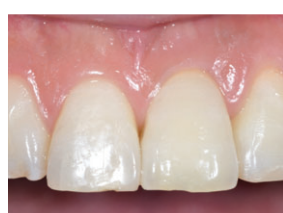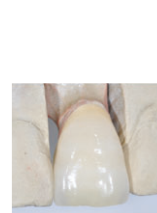
Abutment connection



A new provisional

## • Final Restoration

A metal-ceramic restoration was fabricated on a stone cast taken directly using silicone rubber impression material.



## Conclusions

Customized CAD/CAM abutment system (Osstem SmartFit Abutment) is a promising technique to overcome many shortcomings of conventional readymade abutments or manual milling abutments.

# SmartFit Abutment and Custom Healing Abutment

Ki-Seong Kim  
Scientific Poster, 21st Congress of EAO 2012

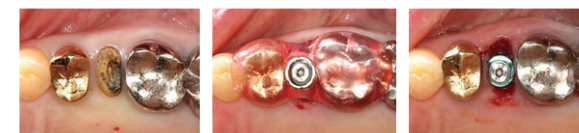## Objective

The latest CAD/CAM technology for patient-specific abutments is now gaining ground on the Korean dental market. Many implant companies are introducing CAD/CAM solution for customized abutment. With CAD/CAM abutments, the clinician can use high-quality, customized abutments with less time and effort. Fixture placement in undesirable conditions must be overcome with restorative procedures. Usually, in such cases, cast-gold UCLA abutments have been used to make customized abutments.

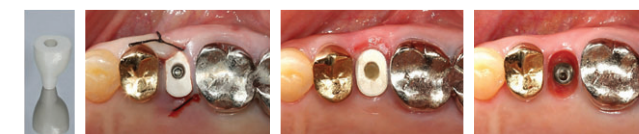Note, however, that cast-gold UCLA abutments have limitations such as increased expenses, casting defects, variable quality depending on the technician's experience, and biocompatibility. These limitations will be overcome with SmartFit abutments for Osstem implants to which CAD/CAM technology was applied. Moreover, clinicians can control the emergence profile and subgingival contour of implant prostheses with customizable healing abutment. Custom healing abutment can be a new option for successful implant prosthetics.

In this poster, I would like to introduce two clinical cases of patient-specific SmartFit abutment and Custom healing abutment.

## Study design (Case Report)



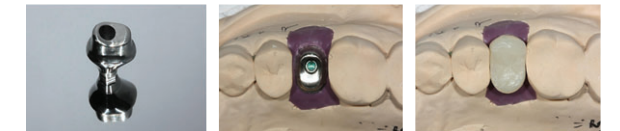Maxillary premolar tooth with retained root was extracted. By using surgical guide, TSIII SA fixture (4X11.5) was placed in #25 missing area.



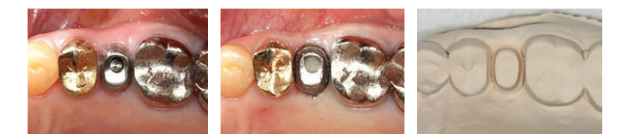Custom healing abutment was connected in the fixture. Well-formed, oval-shape subgingival contour was made with soft tissue sculpting using Custom healing abutment.



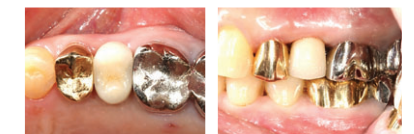Fixture-level impression with transfer impression coping was taken very quickly for preventing slumping of formed soft tissue contour. Subgingival contour was duplicated in the impression body. And Oval shape subgingival contour over #25 fixture was shown in working model.



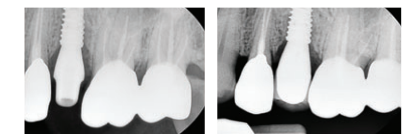
Patient-specific SmartFit abutment was manufactured by milling process in the Osstem CAD/CAM Center. By using the transfer jig, delivered abutment was positioned on the working model and checked. Then provisional restoration was made on the model.



Through a transfer jig, finished SmartFit abutment was positioned onto implant. After the provisional period, the abutment margin was exposed using the retraction cord, and then direct abutment level impression was made.



A Porcelain-veneered metal crown was made as final prosthesis. Emergence profile of #25 final prosthesis is similar to that of adjacent natural tooth restoration.



Periapical radiographs of abutment and final prosthesis.

## Conclusions

SmartFit abutment with Custom healing abutment provides an anatomically optimal emergence profile for implant prosthesis, maximizing long-term aesthetics and function.

As the biggest advantages of SmartFit abutment, it overcomes the limitations of stock abutment and is a useful adjunctive tool for producing restorations that approximate natural teeth in various bad conditions.

With Custom healing abutment and SmartFit abutment for Osstem implant systems, clinicians can improve profitability by eliminating time and cost that have been spent on making cast-gold UCLA abutments.

Furthermore, they provide patients with patient-specific, customized, well-fitting abutment and brings about win-win results for both clinicians and patients.

# Clinical Comparative Study of Immediate Loading Using Tapered Implant with Hydroxyapatite Coating at the Partial Edentulous Ridge of Posterior Maxilla and Mandible

Ji-Young Lee, Young-Kyun Kim  
Scientific Poster, 21st Congress of EAO 2012

## Objective

The aim of this study is to compare the clinical outcome after the immediate loading of two types of implants with a hydroxyapatite coat for patients with missing molar teeth.

## Materials & Methods

### \* Subject :

- Group I : Osstem TSIII HA (Male 12, Female: 15, Total: 27)
- Group II : Zimmer (Male 18, Female: 5, Total: 23)
- Group I and group II were assigned randomly and operator was informed about the study group the day of operation
- Patients who undertook loading within 48 hours of implant installation were included in this study

### \* Implant distribution:

- Group I : maxilla 22, mandible 32, total: 54
- Group II : maxilla 24, mandible 22, total: 46

### \* Average Age

- Group I : 51.40 (11.30) years
- Group II : 49.73 (14.23) years

### \* Evaluation factor

- Marginal bone loss : 1 years after loading
- Soft tissue condition around implant
- Primary and 2nd implant stability (Osstell Mentor device)

\* An Independent T test was conducted to determine the statistical significance (SPSS program, P-value <0.05).

## Results

1. There were no implant failures in both group and survival rate was 100% 12 months after immediate loading. The number of cases showing the bone loss more than 1 mm was 3 in group I, 5 in group II. Implant success rate of group I was 94.4%, group II 89.1%.

2. Mean marginal bone loss was 0.06 mm in group I, 0.44 mm in group II after 1 year. Marginal bone loss of group I was significantly lower than group II (P < 0.05).

Table1. Comparison of marginal bone loss

	Group I(n=54)	Group II(n=46)	Sig*
1 year	0.063(0.66)	0.44(0.65)	*

Independent T test, \*: P-value<0.05

Table2. Comparison of marginal bone loss between groups according to site

	Group I	Group II	Sig*
Maxilla	0.32(0.67)(n=22)	0.66(0.74)(n=24)	-
Mandible	-0.12(0.60)(n=32)	0.19(0.42)(n=22)	*

Independent T test, \*: P-value<0.05

3. There were no significant differences in peri-implant indices such calculus, pocket depth, and width of nonkeratinized mucosa of both groups except plaque index.. Peri-implant tissue condition was stable in both groups.

Table3. Comparison of Peri-implant index between groups

	Group I(n=54)	Group II(n=46)	Sig*
PI	0.28(0.41)	0.50(0.54)	*
CI	0.02(0.13)	0.07(0.24)	-
SBI	0.24(0.44)	0.29(0.41)	-
PD(B)	3.13(1.03)	3.28(1.45)	-
PD(L)	3.13(1.05)	3.31(1.15)	-
PD(M)	3.54(1.27)	4.00(1.71)	-
PD(D)	3.56(1.20)	3.52(1.09)	-
Attached gingiva(B)	3.48(1.88)	3.39(1.34)	-
Attached gingiva(L)	1.12(1.39)	1.08(1.37)	-

Independent T test, \*: P-value<0.05

Table4. Peri-implant index according to site <maxilla>

	Group I(n=22)	Group II(n=24)	Sig*
PI	0.23(0.38)	0.62(0.57)	*
CI	0.00(0.00)	0.14(0.33)	*
SBI	0.22(0.49)	0.34(0.40)	-
PD(B)	3.34(1.42)	3.42(1.50)	-
PD(L)	3.38(1.21)	3.43(1.10)	-
PD(M)	3.68(1.56)	4.33(2.03)	-
PD(D)	3.78(1.32)	3.84(1.04)	-
Attached gingiva(B)	4.04(2.63)	3.75(1.22)	-
Attached gingiva(L)	0.54(0.77)	0.54(0.55)	-

Independent T test, \*: P-value<0.05

Table5. Peri-implant index according to site <mandible>

	Group I(n=32)	Group II(n=22)	Sig*
PI	0.312(0.44)	0.36(0.49)	-
CI	0.03(0.17)	0.25(0.42)	-
SBI	0.25(0.41)	0.23(0.43)	-
PD(B)	2.99(0.65)	3.13(1.42)	-
PD(L)	2.95(0.91)	3.18(1.22)	-
PD(M)	3.44(1.03)	3.63(1.21)	-
PD(D)	3.41(1.11)	3.18(1.05)	-
Attached gingiva(B)	3.10(1.01)	3.00(1.38)	-
Attached gingiva(L)	1.51(1.58)	1.68(1.73)	-

Independent T test, \*: P-value<0.05

4. As implant primary and 2nd stability, There was no significant differences between two groups (P > 0.05). And also there was no significant differences when comparing the each arch between groups (P > 0.05).

Table6. Comparison of ISQ between Group I and Group II

	Group I(n=54)	Group II(n=46)	Sig*
1st(BL)	75.93(8.00)	77.43(5.72)	-
1st(MD)	77.40(6.50)	77.58(6.74)	-
2nd(BL)	83.32(4.74)	83.04(4.42)	-
2nd(MD)	84.42(4.70)	83.08(4.26)	-

Independent T test, \*: P-value<0.05

## Conclusions

The marginal bone loss of implant after immediate loading of two types of study implants with hydroxyapatite coat in patients with missing molar teeth was insignificant. And TSIII HA implant showed more stable result on the aspect of marginal bone status around implant after immediate loading.

# Effect of Microthreads on Removal Torque and Bone-to-Implant Contact: an Experimental Study in Miniature Pigs

Yee-Seo Kwon, Hee Namgoong, Jung-Hoon Kim, In-Hee Cho, Myung-Duk Kim, Tae-Gwan Eom, Ki-Tae Koo  
J Periodontal Implant Sci 2013;43:41-6

## Objective

The objective of this study was to evaluate the effect of microthreads on removal torque and bone-to-implant contact (BIC).

## Materials & Methods

Twelve miniature pigs for each experiment, a total of 24 animals, were used. In the removal torque analysis, each animal received 2 types of implants in each tibia, which were treated with sandblasting and acid etching but with or without microthreads at the marginal portion. The animals were sacrificed after 4, 8, or 12 weeks of healing. Each subgroup consisted of 4 animals, and the tibias were extracted and removal torque was measured. In the BIC analysis, each animal received 3 types of implants. Two types of implants were used for the removal torque test and another type of implant served as the control. The BIC experiment was conducted in the mandible of the animals. The P1-M1 teeth were extracted, and after a 4-month healing period, 3 each of the 2 types of implants were placed, with one type on each side of the mandible, for a total of 6 implants per animal. The animals were sacrificed after a 2-, 4-, or 8-week healing period. Each subgroup consisted of 4 animals. The mandibles were extracted, specimens were processed, and BIC was analyzed.




Fig. 1. Design of implants used in the experiment.

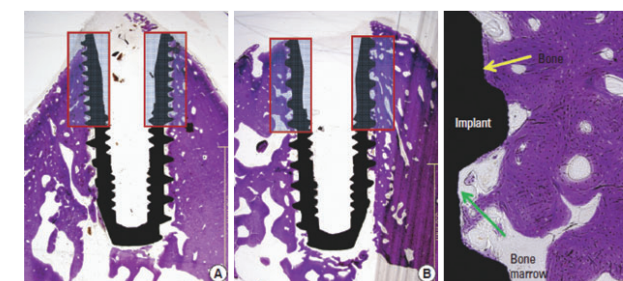


Fig. 2. Cross section of implant in mandible. A) Implant group A. B) Implant Group B. C) Larger magnification of the marginal portion where the BIC measurement was performed.

## Results

No significant difference in removal torque value or BIC was found between implants with and without microthreads. The removal torque value increased between 4 and 8 weeks of healing for both types of implants, but there was no significant difference between 8 and 12 weeks. The percentage of BIC increased between 2 and 4 weeks for all types of implants, but there was no significant difference between 4 and 8 weeks.

## Conclusions

The existence of microthreads was not a significant factor in mechanical and histological stability.

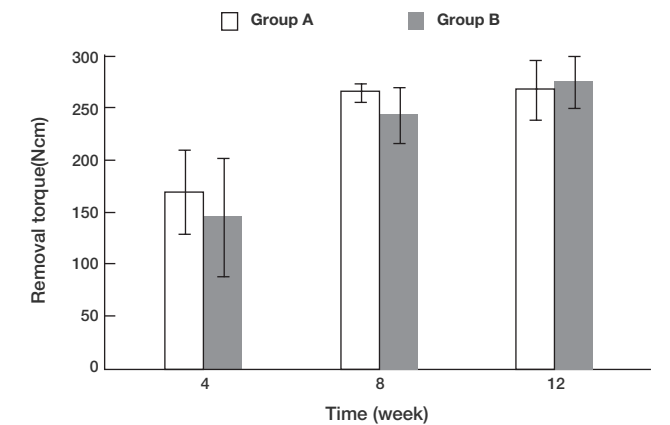


Fig. 3. Mean and standard deviation of removal torque(Ncm) at each healing period.

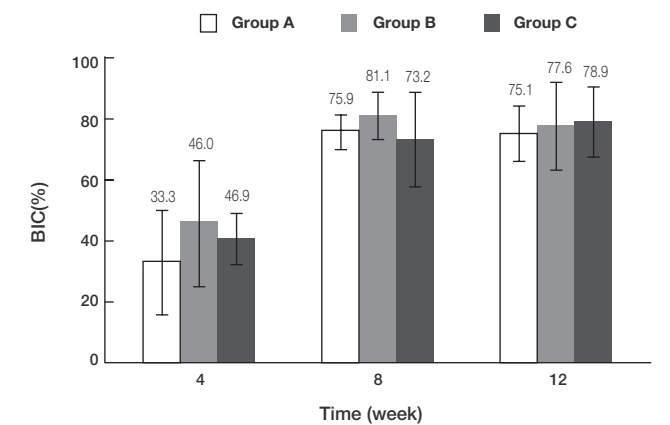


Fig. 4. Mean and standard deviation of BIC(%) at each healing period. BIC:bone-to-implant contact.

# Enhancement of in Vitro Osteogenesis to Chemically Activated CA Surface Compared with SA Surface

Hong-Young Choi, Jae-June Park, Su-Kyung Kim, Tae-Gwan Eom  
Scientific Poster, Osstem Meeting, 2013

## Objective

The aim of study was to evaluate the effect of chemically surface modification with hydrophilicity on various physiochemical parameters which involved with in vitro osteogenesis.

## Materials & Methods

### 1. Preparation of titanium disks

Two types of commercially pure titanium (Grade 3) disks with 12mm in diameter and 1mm in thickness were prepared.

- 1) SA surface: Hydrophobic surface by Sandblasting with  $Al_2O_3$  and acid etching with  $HCl/H_2SO_4$
- 2) CA surface: Super-hydrophilic SA by reducing atmospheric carbon contamination and storing in a solution of calcium.

### 2. Surface characterization and in-vitro evaluation

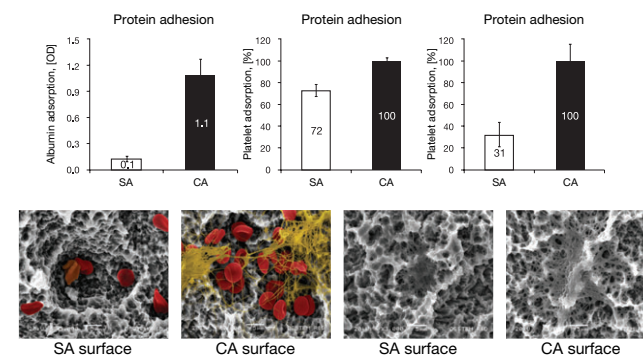
After surface treatment, we verified the surface topography, chemical composition and blood-wettability between two surfaces by SEM, EDS, contact angle measurement. The biological efficiency of chemically activated surface is evaluated by various in-vitro tests such as protein adsorption, platelet activity, osteoblastic cell behavior.

## Conclusions

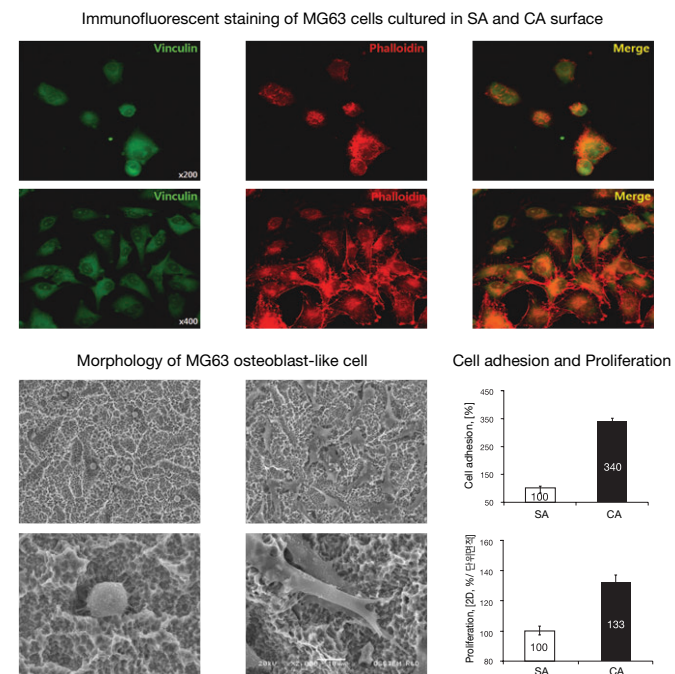
In this study, we verified the chemistry and wettability of titanium surface were important variables in determining protein and osteoblastic cell response. Albumin adsorption, platelet adsorption and activation on chemically activated CA surface was dramatically enhanced compared with hydrophobic SA surface. Also, these super-hydrophilic CA surface showed higher osteoblastic response such as cell adhesion, proliferation, ALP activity, mineralization. Therefore, chemically activated and hydrophilic CA surface may play roles in stimulating the bone formation and ultimately enhanced bone-implant contact compared with hydrophobic SA surface.

## Results

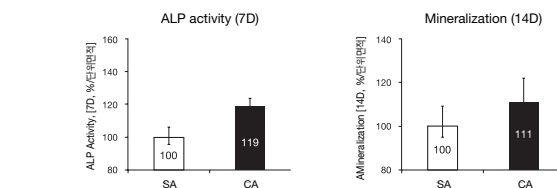
### 1. Protein and platelet response on CA is much higher than SA



### 2. Hydrophilic CA surface enhances the cell spreading behavior.



### 3. Hydrophilic CA surface accelerate ALP activity and Mineralization



# Effect of Photodynamic Therapy on *Aggregatibacter Actinomycetemcomitans* Attached on Titanium Surfaces

Eul-Rak Song, Kyung-Won Cho, Jae-Kwan Lee, Heung-Sik Um, Beom-Seok Chang, Si-Young Lee  
Scientific Poster, Osstem Meeting, 2013

## Objective

Peri-implantitis is an inflammatory process affecting the tissues around an osseointegrated implant. As the need of finding more safe and proper treatment for peri-implantitis arose, more attention is focused on noninvasive photodynamic therapy (PDT) in the treatment of peri-implantitis.

The purpose of this study is to assess the efficacy of PDT using erythrosine and green color light emitting diode (LED) light source to the biofilm of *Aggregatibacter actinomycetemcomitans* attached on resorbable blasted media (RBM) and sand blasted, large grit, acid etched (SLA) titanium surface in vitro.

## Materials & Methods

*A. actinomycetemcomitans* ATCC 33384 was cultivated in trypticase soy broth under anaerobic conditions for 72 hours. After incubating, all disks were rinsed twice with phosphate buffered saline (PBS). RBM and SLA surface of disks were examined by scanning electron microscope (SEM, x 10,000, x 30,000) used to examine the bacteria attached on titanium disks. RBM and SLA disks were subdivided into four groups including one control group and three test groups (E0, E30, E60) for PDT examination for each surface.

RBM	Treatment	N
Control	No treatment	5
E0	20 $\mu$ M Erythrosine 60 seconds	5
E30	20 $\mu$ M Erythrosine 60 seconds + LED light 30 seconds	5
E60	20 $\mu$ M Erythrosine 60 seconds + LED light 60 seconds	5

SLA	Treatment	N
Control	No treatment	5
E0	20 $\mu$ M Erythrosine 60 seconds	5
E30	20 $\mu$ M Erythrosine 60 seconds + LED light 30 seconds	5
E60	20 $\mu$ M Erythrosine 60 seconds + LED light 60 seconds	5

Irradiation source is light emitting diode (Photron Co. Ltd., Seoul, Korea) with a spectrum of emission ranging from 520 ~ 530 nm for 30 seconds (150 mW/cm<sup>2</sup>, 4.5 J/cm<sup>2</sup>). As photosensitizer, 500  $\mu$ l of 20  $\mu$ M erythrosine was used for 60 seconds.

The disks were put into test tube and agitated with PBS and glass bead for 60 seconds. After agitating, 200  $\mu$ l of solution with detached bacteria was spread directly on brucella blood agar plates. The plates were incubated in anaerobic conditions on brucella blood agar plates for 72 hours at 37° C. Survival rate of bacteria was determined by counting the colony forming units (CFU) after incubation. Additionally, A time-resolved fluorescence confocal microscope was used to observe the distribution of live/dead microorganisms on disk surface.

## Results

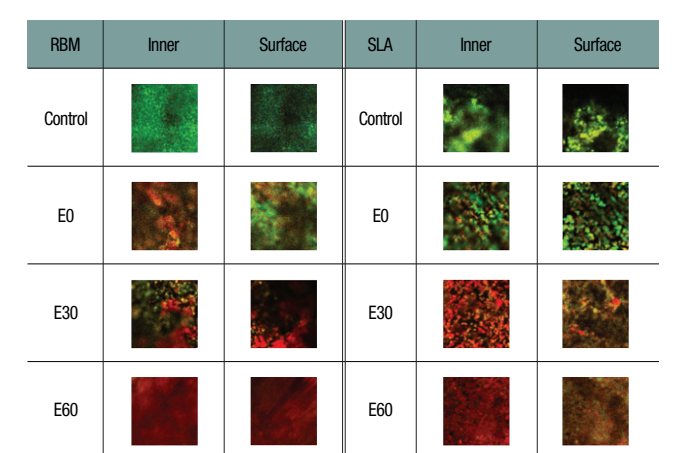
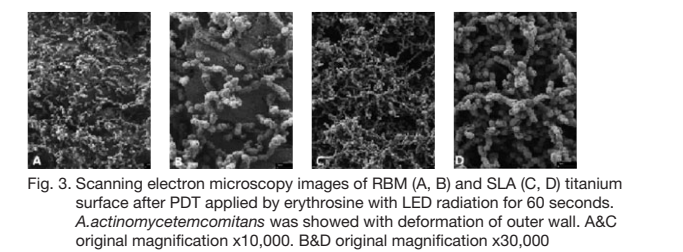




Fig. 4. Confocal images of *A.actinomycetemcomitans* grown on RBM and SLA surfaces. Live bacteria with intact membranes were stained fluorescent green using the SYTO9 stain, while dead bacteria with damaged membranes were stained fluorescent red using propidium iodide.

## Conclusions

Our results demonstrate that association of erythrosine and a green LED, with wavelength 520 ~ 530 nm, light intensity 150 mW/cm<sup>2</sup>, 4.5 J/cm<sup>2</sup> was effective in reducing the viability of *A. actinomycetemcomitans* attached to RBM and SLA titanium surfaces in vitro.

## Evaluation of Biomechanical Effect on Chemically Modified CA Surface in Vivo

Hee Jin Gu, Su-Kyoung Kim, Hong-Young Choi, Myung-Duk Kim, Yong-Seok Cho, Tae-Gwan Eom  
Scientific Poster, 21st Congress of EAO 2012

### Objective

The aim of the study was to evaluate the effect of chemically modified hydrophilic CA surface compared with conventional SA surface in various animals.

### Materials & Methods

A total of 20 implants were divided into two groups. Group 1, implants treated with SA were used as control group. Group 2 retained chemically modified hydrophilic CA surface. All implants were placed in the tibiae of 3 female New Zealand white rabbits and in the mandible of 2 male miniature pigs. Removal torque was measured 16 days after placement.

### Results

In tibiae of rabbit, group 1 had a mean removal torque of 50 Ncm versus 72 Ncm for group 2 after 16 days of healing time. In mandible of miniature pig, group 1 had a mean removal torque of 68 Ncm versus 75 Ncm for group 2 after 2 weeks of healing time. Group 2 was measured more stable anchorage than group 1 in both animals.

### Conclusions

It is concluded that modified hydrophilic CA surfaces were more effective for bio mechanical properties of bone-implant contact from conventional SA surface in rabbits and miniature pigs.

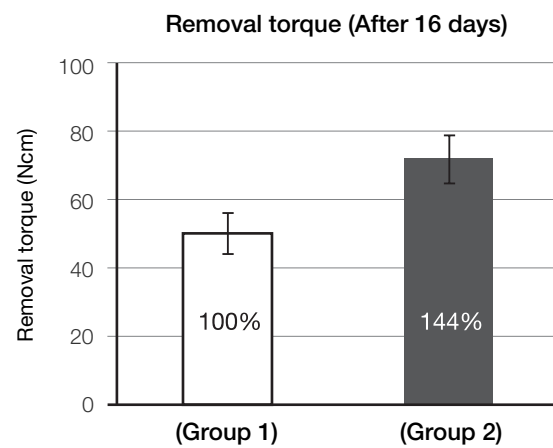


Fig. 1. The result of Removal torque in tibia of rabbits. Group 2 increased more than 40% of mean value compared with group. The sample size for group was 5.

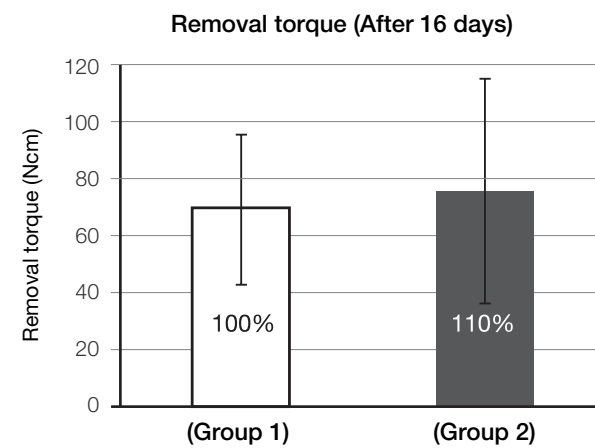


Fig. 2. The result of Removal torque in mandible of miniature pigs. Group 2 increased more than 10% of mean value compared with group. The sample size for group was 10.

## Biomechanical and Histomorphometrical Evaluation of Bone-Implant Integration at Sand Blasting with Alumina and Acid Etching (SA) Surface

In-Hee Cho, Hong-Young Choi, Woo-Jung Kim, Tae-Gwan Eom  
Scientific Poster, 19th Congress of EAO 2010

### Objective

The implant surface feature and roughness have been proposed as a potential factor affecting bone integration and marginal bone loss. The aim of the present study was to evaluate the difference between SA and RBM surface for osseointegration and marginal bone loss in the mandible of beagle dogs.

### Materials & Methods

All mandibular premolars and first molars were extracted bilaterally in 10 beagles. After 8 weeks of extraction, 48 implants (22 SA surface implants and 26 RBM surface implants) were implanted in the mandible of beagle dogs. After 12 weeks of healing, the implants were evaluated marginal bone levels, histomorphometric analysis and removal torque. 36 implants were used for the removal torque test. 12 implants were processed for histomorphometric analysis. For statistical analysis, t-tests were performed ( $p < .05$ ).

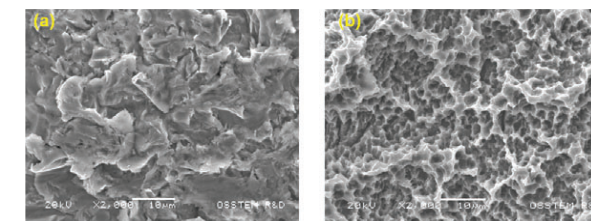


Fig. 1. SEM micrographs of titanium implant surfaces (a) RBM surface, (b) SA surface.

### Results

There were no statistically significant differences in relation to histomorphometric evaluations between RBM and SA surfaces. Marginal bone loss was  $0.83 \pm 0.51$  mm (RBM surface) and  $0.96 \pm 0.43$  mm (SA surface). No differences could be observed between the two surfaces of implants. After a 12 weeks healing period, BIC and BA of SA surface were similar to the RBM surface. There were no significant differences in the BIC and BA between the two groups ( $p > .05$ ). The mean removal torque value was higher for a SA surface ( $127.2 \pm 37.0$  Ncm) than for a RBM surface ( $61.9 \pm 34.5$  Ncm). The differences between RBM and SA surfaces were significant ( $p < .001$ ).

### Conclusions

It can be concluded that the SA surface was more effective than RBM surface in enhancing the biomechanical interlocking between the new bone and implant.

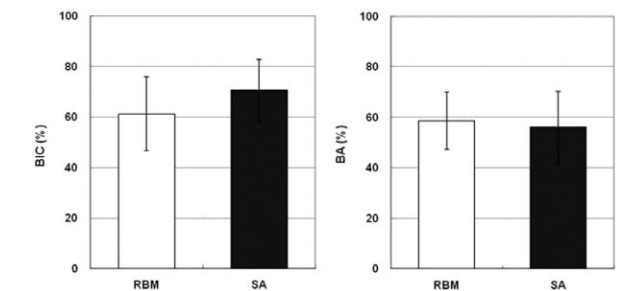


Fig. 3. Histomorphometric analysis (BIC and BA).

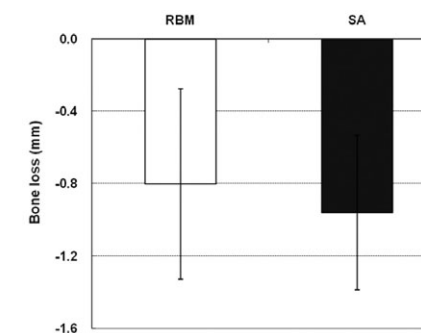


Fig. 2. Changes in the marginal bone levels of RBM and SA.

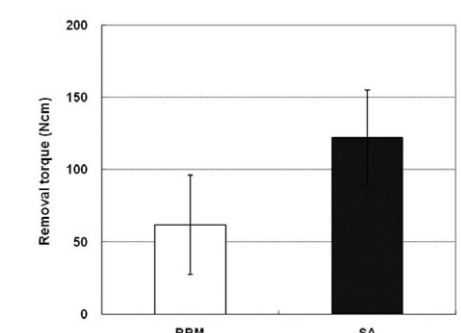


Fig. 4. Removal torque values (Ncm).

# Experimental Study of Bone Response to Hydroxyapatite Coating Implants: BIC and Removal Torque Test

Tae-Gwan Eom, Gyeo-Rok Jeon, Chang-Mo Jeong, Young-Kyun Kim, Su-Gwan Kim, In-Hee Cho, Yong-Seok Cho, Ji-Su Oh  
Oral Surg Oral Med Oral Pathol Oral Radiol 2012;114(4):411-8

## Objective

The objective of this study was to evaluate the early osseointegration of hydroxyapatite (HA) coated implant versus resorbable blast media (RBM) and sand-blasted with alumina and acid etched (SA) surface tapered implants.

## Materials & Methods

Twelve adult male miniature pigs (Medi Kinetics Micropigs, Medi Kinetics Co., Ltd., Korea) were used in this study. The removal torque of implants placed in the tibia of miniature pigs was measured. For implants placed in the mandible, histomorphometric evaluation was performed for the evaluation of the bone-implant contact (BIC) ratio.

## Results

After 4, 8, and 12 weeks, removal torque values were increased. Among the 3 groups, the HA coated group showed the highest value ( $p < .05$ ). When the HA surface, RBM, and SA surface group were compared at each time point, the HA group showed statistically significantly high removal torque value (RTV) values ( $p < .05$ ). At 2 weeks, in comparison with RBM, SA showed an 11 % increase, and HA showed a 42 % increase; nonetheless, they were not statistically significant. At 4 weeks, the BIC ratio of HA was significantly higher than that of SA ( $p < .05$ ). Nonetheless, RBM and SA were not significantly different ( $p > .05$ ). At 8 weeks, the BIC of HA was shown to be significantly higher than RBM or SA ( $p < .05$ ). Nonetheless, RBM and SA were not significantly different ( $p > .05$ ).

## Conclusions

The early osseointegration of HA coated implants was found to be excellent, and HA coated implants will be available in poor quality bone.

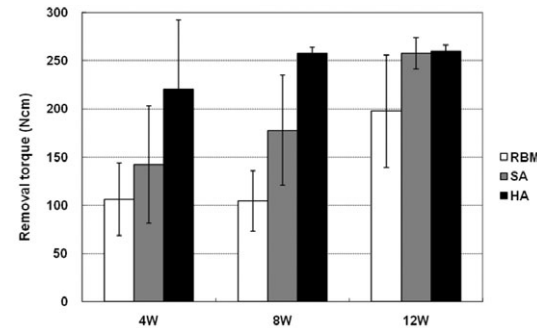


Fig. 1. Removal torque value graph.

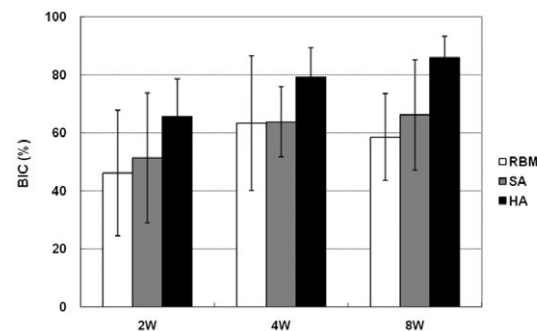


Fig. 2. BIC ratio.

# Comparative Study on the Durability of Abutment Post According to Tightening Torque and Cantilever Volume

Jae-Chan Heo, Jae-Ho Ryu, Jung-Hwa Oh, Tae-Hyung Kim, Tae-Gwan Eom  
Scientific Poster, Osstem Meeting, 2013

## Objective

This study sought to do a comparative evaluation of the abutment post's fatigue life experimentally according to the tightening torque and cantilever volume, thereby emphasizing the importance of tightening torque specified by the manufacturer and suggesting a guide to designing prosthesis with excellent long-term stability so that it can be applied correctly to actual clinical cases.

## Materials & Methods

### 1. Materials

#### 1) Specification

Part	Spec.
Fixture	TSII SA Fixture $\phi 4.0 \times 11.5\text{mm}$
Abutment	TS Transfer Abutment $\phi 5.0, G/H 2\text{mm}, H5.5\text{mm}$
Screw	EbonyGold Screw Regular screw

#### 2) Test group VS. control group (N= 5 EA)

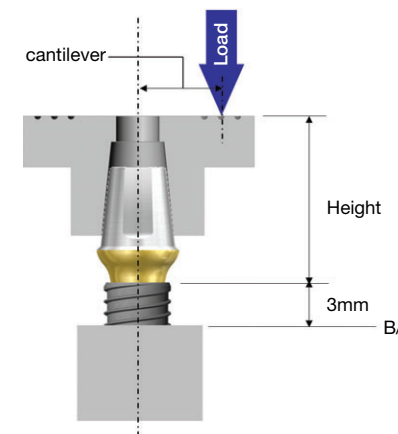
Test	Tightening Torque	SpecCantilever
Test group	20Ncm, 25Ncm, 35Ncm, 40Ncm	6mm, 5mm, 4mm
Control group	30Ncm	-

### 2. Test equipments

- 1) Fatigue tester: Instron 8841
- 2) Torque Gage: Mark-10's MGT12

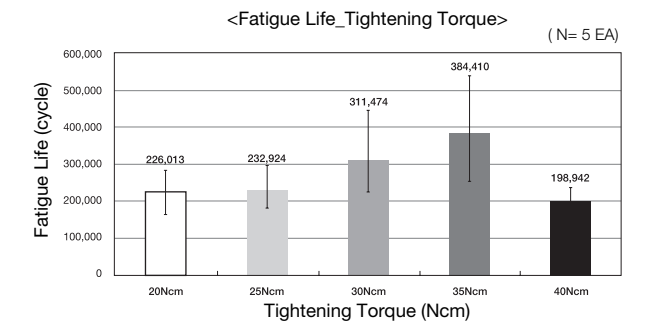


### 3. Methods

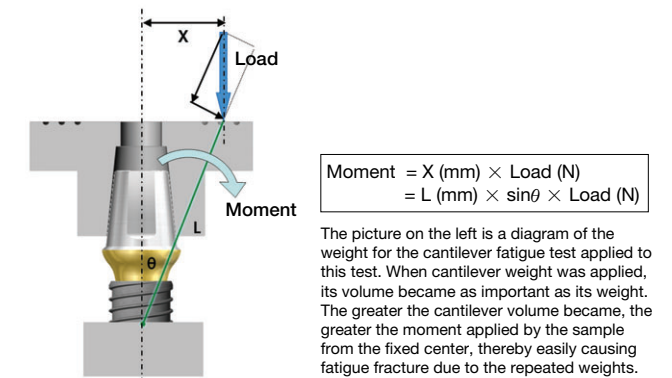
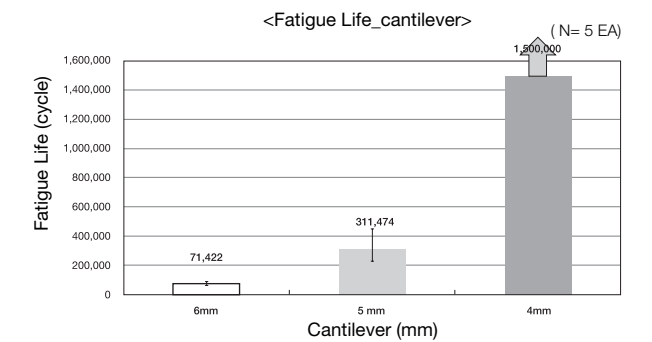


## Results

### 1. Comparative test of fatigue life according to tightening torque



### 2. Comparative test of fatigue life according to cantilever volume



## Conclusions

As can be seen from the comparative test of fatigue life according to the tightening torque and cantilever volume, connecting with torque beyond or below the manufacturer-specified value shortens the fatigue life, requiring periodic checks of instruments as well as caution during actual use. Moreover, since greater cantilever volume results in shorter fatigue life, occlusal prosthesis should be considered from the fixture's procedure level. Occlusal strength and antagonist tooth should also be considered when manufacturing the prosthesis to produce one with outstanding fatigue fracture performance.

## TS SYSTEM References

### Clinical Study

1. Young-Kyun Kim, Ji-Hyun Bae. Subjective satisfaction of clinician and Short-term Clinical Evaluation of Osstem TSIII SA Implant. J Korean Clinical Implant 2010;30(7):430-43
2. Ki-Seong Kim. Considerations in Using Patient-Specific Computer Aided Design/Computer Aided Manufacturing (CAD/CAM) Titanium Abutment. Implantology 2013;17(1):2-14
3. Yong-Jin Kim, Young-Jin Park, Kyung-Tae Park. Case report of Guided Bone regeneration in dehiscence-type defects using hydrophilic surfaced implant(TSIII CA) and SMARTbuilder. Scientific Poster, Osstem Meeting 2013
4. Seung-Hwan Jeon, Kyung-Gyun Hwang, Chang-Joo Park. Preliminary clinical evaluation of customized three-dimensional pre-formed titanium mesh for localized alveolar bone regeneration. Scientific Poster, Osstem Meeting 2013
5. Kun-Soo Chang, Kyung-gyun Hwang, Chang-Joo Park. Preliminary study for hydraulic sinus membrane elevation by CAS KIT without bone graft. Scientific Poster, Osstem Meeting 2013
6. Kyo-Jin Ahn, Young-Kyun Kim. Prospective comparative study of tapered implant with SLA surface at maxillary posterior area according to loading time: 3 and 6 months. Scientific Poster, 21st Congress of EAO 2012
7. Yong-Jin Kim, Young-Jin Park, Kyung-Tae Park. Sinus bone grafting with simultaneous implant placement in case of residual bone height less than 4mm using TSIII SA implant. Scientific Poster, 22nd Congress of EAO 2013
8. Young-Whee Son. Recovery of Alveolar Bone Defect Using Open Membrane Technique with immediate implant placement. Scientific Poster, Osstem Meeting 2013
9. Kwang-Heung Han, Min-Suk Heo. Vertical ridge augmentation with SMARTbuilder in poor bone condition. Scientific Poster, Osstem Meeting 2013
10. Hyung-Sik Do, Young-Il Song, Hwan-Yong Jang, Jin-Yong Lee, Jae-Hyung Lim, Hyun-Seok Jang, Jong-Jin Kwon, Jae-Suk Rim, Eui-Seok Lee. A Case of Rehabilitation of Oral Function with Dental Implants Following Panfacial Bone Fracture. Scientific Poster, Osstem Meeting 2013
11. Yong-Jin Kim, Young-Jin Park, Kyung-Tae Park. Case report of Flapless implant surgery with TSIII SA implant; Soft tissue access hole using a round-ended, high-speed diamond bur. Scientific Poster, Osstem Meeting 2013
12. Jung-Gil Han, Kwan-Soo Park. A case report of TSIII implant-immediate flapless placement of a molar tooth with CAS KIT sinus augmentation involving membrane perforation perforation. Scientific Poster, Osstem Meeting 2013
13. Young-Il Oh, Kwan-Soo Park. Immediate flapless placement of incisor, premolar and molar - a case of TSIII implant. Scientific Poster, Osstem Meeting 2013
14. Hseuh-Yu Li, Kwan-Soo Park. An experience of immediate flapless placement of TSIII without drilling and initial stability. Scientific Poster, Osstem Meeting 2013
15. Hyun-Ki Cho. Immediate placement and loading of dental implants. Clinical result. Scientific Poster, Osstem Meeting 2013
16. Young-Hak Oh. Immediate Loading of the Edentulous Maxilla: a case series. Scientific Poster, Osstem Meeting 2013
17. Choon-Mo Yang. Immediate implant placement and immediate loading with Osstem TSIII implants and chair-side provisional restoration in mandibular anterior partial edentulism. Scientific Poster, 21st Congress of EAO 2012
18. Choon-Mo Yang. Full mouth rehabilitation utilizing the CAD/CAM Technology : Surgical Guide for Flapless surgery, Provisional restoration and screw-retained Fixed Complete Denture. Scientific Poster, 21st Congress of EAO 2012
19. Byung-Ho Kim, In-Jae Won. Case of Restoration with Fixed Prosthesis for Maxillary Anterior Implants Using SMARTbuilder and SmartFit. Scientific Poster, Osstem Meeting 2013
20. Jong-Hwan Park. SmartFit Abutment case report. Scientific Poster, Osstem Meeting 2013
21. Hwee-Woong Park. An Implant-Supported Restoration of a Maxillary Central Incisor Using a Temporary Abutment and a Customized CAD/CAM Titanium Abutment. Scientific Poster, 21st Congress of EAO 2012
22. Ki-Seong Kim. SmartFit Abutment and Smart Healing Abutment. Scientific Poster, 21st Congress of EAO 2012
23. Choon-Mo Yang. Provisionalization of Implant Restorations with PEEK Temporary Abutments. Scientific Poster, Osstem Meeting 2013
24. Yong-Jin Kim, Young-Jin Park, Kyung-Tae Park. Maxillary anterior bone augmentation using B-Oss (Newly Developed Deproteinized Inorganic Bovine Xenograft). Scientific Poster, 22nd Congress of EAO 2013
25. Ji-Young, Lee. Young-Kyun Kim. Clinical comparative study of immediate loading using tapered implant with hydroxyapatite coating at the partial edentulous ridge of posterior maxilla and mandible. Scientific Poster, 21st Congress of EAO 2012

### Pre-Clinical Study Biology

1. Yee-Seo Kwon, Hee Namgoong, Jung-Hoon Kim, In-Hee Cho, Myung-Duk Kim, Tae-Gwan Eom, Ki-Tae Koo. Effect of microthreads on removal torque and bone-to-implant contact: an experimental study in miniature pigs. J Periodontal Implant Sci 2013;43:41-6
2. Hong-Young Choi, Jae-June Park, Su-Kyung Kim, Tae-Gwan Eom. Enhancement of in vitro osteogenesis to chemically activated CA surface compared with SA surface. Scientific Poster, Osstem Meeting 2013
3. Eul-Rak Song, Kyung-Won Cho, Jae-Kwan Lee, Heung-Sik Um, Beom-Seok Chang, Si-Young Lee. Effect of photodynamic therapy on aggregatibacter actinomycetemcomitans attached on titanium surfaces. Scientific Poster, Osstem Meeting 2013
4. Kyung-Won Ha, Woo-Jung Kim, Kin-Won Hong, Hyun-Man Kim. High Osseointegration Rate of BA Implant. Scientific Poster, Osstem Meeting 2013
5. Hee-Jin Gu, Su-Kyoung Kim, Hong-Young Choi, Myung-Duk Kim, Yong-Seok Cho, Tae-Gwan Eom. Evaluation of biomechanical effect on chemically modified Ca-SA surface in vivo. Scientific Poster, 21st Congress of EAO 2012
6. Hong-Young Choi, Su-Kyung Kim, Jae-Jun Park, Tae-Gwan Eom. Enhancement of in Vitro Osteogenesis on Sandblasted and Acid Etched Surfaces with Rough Micro-topography. Scientific Poster, Osstem World Meeting 2011
7. Hong-Young Choi, Jae-June Park, Su-Kyung Kim, Tae-Gwan Eom. The Effects of Surface Roughness on the Sandblasted with Large Grit Alumina and Acid Etched Surface Treatment: In Vitro Evaluation. Scientific Poster, Osstem World Meeting 2011
8. Hong-Young Choi, Jae-June Park, In-Hee Cho, Tae-Gwan Eom. The Effects of Surface Roughness on the Sandblasted with Large Grit Alumina and Acid Etched Surface Treatment: In Vivo Evaluation. Scientific Poster, Osstem World Meeting 2011
9. In-Hee Cho, Hong-Young Choi, Woo-Jung Kim, Tae-Gwan Eom. Biomechanical and Histomorphometrical Evaluation of Bone-Implant Integration at Sand Blasting with Alumina and Acid Etching (SA) Surface. Scientific Poster, 19th Congress of EAO 2010
10. Tae-Gwan Eom, Gyeo-Rok Jeon, Chang-Mo Jeong, Young-Kyun Kim, Su-Gwan Kim, In-Hee Cho, Yong-Seok Cho, Ji-Su Oh. Experimental Study of Bone Response to Hydroxyapatite Coating Implants: BIC and Removal Torque Test. Oral Surg Oral Med Oral Pathol Oral Radiol 2012;114(4):411-8
11. Tae-Gwan Eom, Young-Kyun Kim, Jong-Hwa Kim, In-Hee Cho, Chang-Mo Jeong, Yong-Seok Cho. Experimental Study about the Bony Healing of Hydroxyapatite Coating Implants. J Korean Assoc Oral Maxillofac Surg 2011;37(4):295-300
12. Min-Woo Kim, Tae-Gwan Eom. Surface Property Evaluation According to the High Crystallinity of the TSIII HA Implant. Scientific Poster, Osstem World Meeting 2011
13. June-Cheol Hwang, Hong-Young Choi, Tae-Gwan Eom. Architectural Feature of TSIII HA Implant. Scientific Poster, Osstem World Meeting 2011

### Pre-Clinical Study Biomechanics

1. Jae-Chan Heo, Jae-Ho Ryu, Jung-Hwa Oh, Tae-Hyung Kim, Tae-Gwan Eom. Comparative study on the durability of abutment post according to tightening torque and cantilever volume. Scientific Poster, Osstem Meeting 2013
2. Yung-Soo Kim, Young-Jun Lim. Primary Stability and Self-Tapping Blades: Biomechanical Assessment of Dental Implants in Medium-Density Bone. Clin. Oral Impl. Res. 2011(22) 1179-84
3. Duck-Rae Kim, Young-Jun Lim, Myung-Joo Kim, Ho-Beom Kwon, Sung-Hun Kim. Self-Cutting Blades and their Influence on Primary Stability of Tapered Dental Implants in a Simulated Low-Density Bone Model: a laboratory study. Oral Surg Oral Med Oral Pathol Oral Radiol Endod 2011(112);573-80
4. Tae-Gwan Eom, Seung-Woo Suh, Myung-Duk Kim, Young-Kyun Kim, Seok-Gyu Kim. Influence of Implant Length and Insertion Depth on Stress Analysis: a Finite Element Study. Scientific Poster, Academy of KSME 2011
5. Tae-Gwan Eom, In-Ho Kim, Insertion Torque Sensitivity of TSIV SA Fixture in Artificial Bone Model. Scientific Poster, Osstem World Meeting 2011

## A Multicenter Prospective Study in Type IV Bone of a Single Type of Implant

Mi-Ae Jeong, Su-Gwan Kim, Young-Kyun Kim, Hee-Kyun Oh, Yong-Seok Cho, Woo-Cheol Kim, Ji-Su Oh  
 Implant Dent. 2012 Aug;21(4):330-4

### Objective

To analyze the success and survival rates of the Osstem GSII (Osstem, Seoul, Korea) implant in type IV bone.

### Materials & Methods

A prospective, multicenter (5 centers) study was conducted by examining the relationship between implant success and survival rates, and several patient and surgical parameters. The implants were placed in 82 patients who visited several nationwide dental hospitals and clinics between 2007 and 2008, followed by clinical and radiographic analyses.

Table 1. General Conditions and Smoking Habit

Diabetes mellitus	13
Cardiovascular disease	13
Hypertension	1
Liver disease	2
Heart disease	2
Smoking habit	17

Table 2. Distribution of Implants by Length and Diameter

Diameter (mm)	Length (mm)						Total
	7	8.5	10	11.5	13	15	
3.5					4	2	6
4.0			9	34	32	1	76
4.5	1		2	2	11	3	19
5.0	8	1	10	31	35	2	87
5.5	1	2			1		4
Total	10	3	21	67	83	8	192

Table 3. Distribution of Operation Methods

Operation Methods	No. of Implants
Sinus lift via osteotome technique	35
Sinus lift via lateral window opening	6
Onlay graft	21
GBR	37
Onlay graft + GBR	5
Split crest + GBR	6
Conventional method	82

Table 4. Clinical Results According to Site

	Osstell Mentor	Mean (wk)	Success Rates, n (%)
Upper anterior tooth	62.3 ± 10.4	17.8	14/15(93.33)
Upper premolars	61.4 ± 10.8	17.7	41/41 (100)
Upper molars	61.4 ± 14.0	17.4	112/115 (97.39)
Lower anterior tooth	59.0 ± 2.8	11.0	2/2 (100)
Lower premolars	62.7 ± 11.5	9.0	2/3 (66.66)
Lower molars	59.0 ± 23.7	13.5	13/16(81.25)

Table 5. Distribution of Implants by Bone Resorption

Amount of Bone Resorption (mm)	No. of Implants
None	179
0-0.9	4
1.0-2.0	6
>2.0	0

### Results

In type IV bone, the implant success and survival rates were 93.23% and 95.83%, respectively. The maxillary premolar and mandibular anterior tooth areas showed success rates of 100%. The most widely used implant diameter and length was 5.0 and 13 mm, respectively, but the diameter and length had no effect on success rates. However, success rates appeared to decrease with age.

### Conclusions

The results indicated that the Osstem GSII implant is highly effective in poor-quality type IV bone.

## Comparison of Clinical Outcomes of Sinus Bone Graft with Simultaneous Implant Placement: 4-Month and 6-Month Final Prosthetic Loading

Young-Kyun Kim, Su-Gwan Kim, Jin-Young Park, Yang-Jin Yi, Ji-Hyun Bae  
 Oral Surg Oral Med Oral Pathol Oral Radiol Endod. 2011 Feb;111(2):164-9

### Objective

The aim of this study was to compare the survival rate and surrounding tissue condition of sinus bone grafts with simultaneous implant placement between 4-month and 6-month occlusal loading after implantation.

### Materials & Methods

Twenty-seven patients (61 implants) who were treated with sinus bone grafts (sinus lateral approach) and simultaneous Osstem GSII implant placement from July 2007 to June 2008 were included in this study. Of these patients, 14 (31 implants) were in the 4-month loading group, and 13 (30 implants) were in the 6-month loading group. We investigated the implantation type (submerged or nonsubmerged), sinus membrane perforation, type of prosthesis, opposed tooth type, primary and secondary stability of implants, and crestal bone loss around implant and surrounding tissue conditions.

Table 1. Condition of the adjacent tissue around the implants

Index	Occlusal loading	
	4 months	6 months
Crestal bone loss (mm)	0.19 ± 0.33	0.39 ± 0.86
Width of keratinized mucosa (mm)	2.50 ± 1.69	1.73 ± 1.40
Plaque index	1.11 ± 0.96	0.76 ± 0.79
Gingival index	0.72 ± 0.83	0.59 ± 0.69
Probing pocket depth (mm)	3.56 ± 0.98	3.65 ± 1.06

Table 2. Residual bone height (mm)

	Occlusal loading	
	4 months	6 months
Before operation	5.38 ± 1.95	4.52 ± 1.71
Immediately after operation	17.26 ± 3.22	16.64 ± 1.87
1 year after operation	15.58 ± 2.03	15.48 ± 2.29

Table 3. Primary and secondary stability (implant stability quotient) of implants

	Occlusal loading	
	4 months	6 months
Primary	61.96 ± 12.84	56.06 ± 15.55
Secondary	71.85 ± 6.80	66.51 ± 11.28

### Results

The amounts of crestal bone-loss at the final recall time (12.56 ± 5.95 month after loading) of the 4-month and 6-month loading groups were 0.19 ± 0.33 mm and 0.39 ± 0.86 mm, respectively. However, the difference between groups was not statistically significant (P=.211). The width of keratinized mucosa, gingival index, plaque index, and pocket depth of the 4-month and 6-month loading groups were 2.50 ± 1.69 mm and 1.73 ± 1.40 mm (P=.081), 0.72 ± 0.83 and 0.59 ± 0.69 (P=.671), 1.11 ± 0.96 and 0.76 ± 0.79 (P=.226), 3.56 ± 0.98 mm and 3.65 ± 1.06 mm (P=.758), respectively. The primary stabilities of implants in the 4-month and 6-month loading groups were 61.96 ± 12.84 and 56.06 ± 15.55 (P=.120), and the secondary stabilities were 71.85 ± 6.80 and 66.51 ± 11.28 (P=.026), respectively. The secondary stability of the 4-month group was significantly higher than that of the 6-month group. There was no statistical difference (P>.05) between the 4-month and 6-month loading groups regarding the implantation type (submerged or nonsubmerged), sinus membrane perforation, type of prosthesis, or opposed tooth type. In the 4-month and 6-month groups, all of the implants survived until the final recall time.

### Conclusions

For the cases in which the residual bone was 3 mm and primary implant stability could be obtained, we conclude that loading is possible 4 months after the sinus bone graft and simultaneous implant placement.



## Prospective Study of Tapered RBM Surface Implant Stability in the Maxillary Posterior Area

Soo-Yeon Kim, Young-Kyun Kim  
Oral Surg Oral Med Oral Pathol Oral Radiol. 2012 Jul;114(1):e19-24

### Objective

The purpose of this study was to evaluate the stability of tapered resorbable blasting media (RBM) surface implants in the posterior maxilla.

### Materials & Methods

From September 2008 through January 2010, 20 patients (9 male, 11 female) who were treated with tapered GSIII implants at Seoul National University Bundang Hospital were identified. Thirty-eight implants (14 premolar and 24 molar) were placed in maxillary posterior areas.

Table 1. ISQ (Implant stability quotient) value change

	1 <sup>st</sup> op	2 <sup>nd</sup> op	p
ISQ	63.6 ± 14.1	74.4 ± 7.2	.000

P was calculated using paired T-test  
\*Indicates statistically significant difference (p<.05)

Table 2. CBL (crestal bone loss) according to time

	3 months	6 months	12 months	p
CBL (mm)	0.05 ± 0.14	0.09 ± 0.24	0.19 ± 0.47	.011

P was calculated using repeated measures ANOVA  
\*Indicates statistically significant difference (P<.05)

Table 3. Implant survival rate of GSIII implants

	Survival	Fail	Survival rate
No.	37	1	97.4%

Table 4. CBL 12 month after final prosthesis delivery according to diameter and length

		CBL	p*
Diameter	Regular	0.09 ± 0.12	.949
	Wide	0.26 ± 0.62	
Length	Normal	0.16 ± 0.24	.404
	Long	0.22 ± 0.61	

\*. Mann-Whitney U-test was performed; insignificant differences were seen according to implant diameter and length (p>.05)

Table 5. Comparison between implants with and without sinus grafts

		With sinus graft (N=9)	Without sinus graft (N=29)	p*
ISQ	1 <sup>st</sup> op	67.6 ± 7.4	62.5 ± 15.7	.501
	2 <sup>nd</sup> op	75.3 ± 6.6	74.0 ± 7.4	.831
CBL	3M	0.01 ± 0.03	0.06 ± 0.16	.452
	6M	0.01 ± 0.03	0.11 ± 0.27	.314
	12M	0.07 ± 0.13	0.23 ± 0.53	.361

\*. Mann-Whitney U-test was performed; insignificant differences were seen between the group with sinus graft and the group without sinus graft (p>.05)

### Results

In this study, 38 taper-shaped implants were placed in 20 patients who were followed up for 1 year. The following conclusions were obtained.

1. Regarding implant stability, the average ISQ value at the time of placement was 63.6 and was 74.4 at the time of the 2nd surgery, which was a significant increase. The cumulative survival rate of 12 months after prosthesis placement was 97.4%, and the success rate was 94.7%.
2. The resorption rate of marginal bones 12 months after prosthesis was an average of 0.19 mm, and stable results were shown. Significant differences according to the diameter and length of implants were not shown.
3. The group that received maxillary sinus bone graft was compared with the group that did not receive the procedure. The ISQ value and the marginal bone resorption rate were not significantly different.

### Conclusions

There was no significant difference in crestal bone loss according to implant diameter or length or sinus bone graft. This study showed the favorable clinical outcome of tapered implants that were placed in the maxillary posterior area.

## A 1-Year Prospective Clinical Study of Soft Tissue Conditions and Marginal Bone Changes Around Dental Implants After Flapless Implant Surgery

Seung-Mi Jeong, Byung-Ho Choi, Ji-Hun Kim, Feng Xuan, Du-Hyeong Lee, Dong-Yub Mo, Chun-Ui Lee  
Oral Surg Oral Med Oral Pathol Oral Radiol Endod. 2011 Jan;111(1):41-6

### Objective

Despite several reports on the clinical outcomes of flapless implant surgery, limited information exists regarding the clinical conditions after flapless implant surgery. The objective of this study was to evaluate the soft tissue conditions and marginal bone changes around dental implants 1 year after flapless implant surgery.

### Materials & Methods

For the study, 432 implants were placed in 241 patients by using a flapless 1-stage procedure. In these patients, peri-implant soft tissue conditions and radiographic marginal bone changes were evaluated 1 year after surgery.

### Results

None of the implants were lost during follow-up, giving a success rate of 100%. The mean probing depth was 2.1 mm (SD 0.7), and the average bleeding on probing index was 0.1 (SD 0.3). The average gingival index score was 0.1 (SD 0.3), and the mean marginal bone loss was 0.3 mm (SD 0.4 mm; range 0.0-1.1 mm). Ten implants exhibited bone loss of >1.0 mm, whereas 125 implants experienced no bone loss at all.

### Conclusions

The results of this study demonstrate that flapless implant surgery is a predictable procedure. In addition, it is advantageous for preserving crestal bone and mucosal health surrounding dental implants.

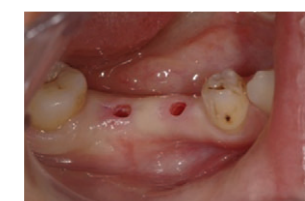

Fig. 1. Clinical features after punching the soft tissue at the proposed implant sites with a 3-mm soft tissue punch.

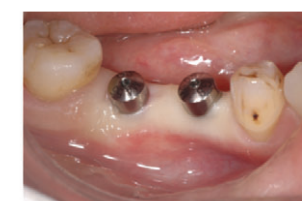

Fig. 2. Clinical features after healing abutments were connected to the fixtures.

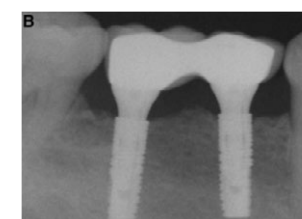
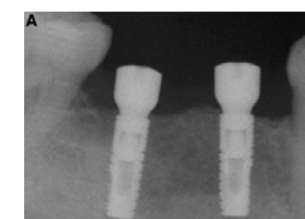


Fig. 3. Periapical radiograph taken immediately (A) and 1 year (B) after implant placement.

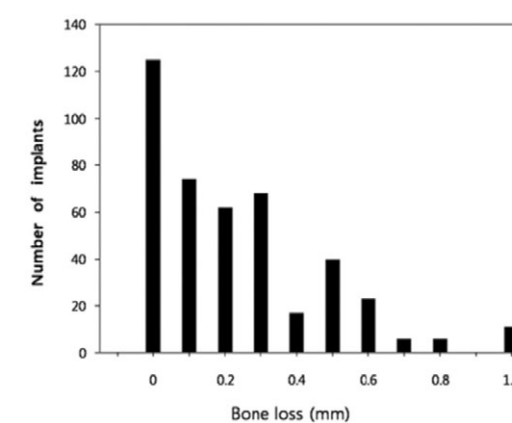


Fig. 4. Number of implants that exhibited varying amounts of bone loss during the healing period from the time of implant placement to the 1-year follow-up.

Table 1. Probing depth, gingival index, bleeding on probing index, and crestal bone loss when implants were placed without a flap

Index	1 year
Probing depth (mm)	2.1 ± 0.7
Bleeding on probing index	0.1 ± 0.3
Gingival index	0.1 ± 0.3
Crestal bone loss	0.3 ± 0.4

## A Relaxed Implant Bed: Implants Placed After Two Weeks of Osteotomy with Immediate Loading: A One Year Clinical Trial

Bansal DJ, Kedige DS, Bansal DA, Anand DS  
J Oral Implantol. 2012 Apr;38(2):155-64

### Objective

A waiting period of two weeks after osteotomy increases the surrounding tissue activity to its maximum level as collagen formation and neoangiogenesis represents a relaxed and acceptable implant bed configuration.

The aim of the present study was a clinical and radiological evaluation of early osteotomy with implant placement delayed for two weeks with immediate loading in the anterior and premolar region with minimally invasive approach.

### Materials & Methods

A total of seven GSII implants (Osstem) were placed in six patients. Osteotomy was done followed by flap closure without the placement of implant. After approximately waiting for a period of two weeks, implant placement was done which were loaded immediately with provisional crown in implant protected occlusion. It was replaced by definitive restoration after 6-8 weeks which was considered as baseline. Implant stability and marginal bone levels were assessed with clinical and radiological parameters at baseline, 6th and 12th month intervals.

Table 1. Mean values of width of keratinized mucosa index

Assessment Time	Mean ± SD	% Change from baseline
Baseline	2.00 ± 0.63	-
6th Month	2.17 ± 0.41	-8.5%
12th Month	2.33 ± 0.52	-16.5%

Table 2. Mean values of peri-implant probing depth

Assessment Time	Mean ± SD	% Change from baseline
Baseline	2.38 ± 0.54	-
6th Month	2.29 ± 0.33	3.36%
12th Month	2.08 ± 0.34	12.18%

### Results

None of the implants were found mobile during the one year period. The amount of average mean marginal bone loss was 0.4 mm over the one year follow up period.

### Conclusions

In the present study, early osteotomy with delayed implant placement showed negligible crestal bone loss with no mobility.

## Evaluation of Sinus Bone Resorption and Marginal Bone Loss After Sinus Bone Grafting and Implant Placement

Young-Kyun Kim, Pil-Young Yun, Su-Gwan Kim, Bum-Soo Kim, Joo L Ong  
Oral Surg Oral Med Oral Pathol Oral Radiol Endod 2009;107:e21-8

### Objective

The objective of this study was to evaluate the sinus bone graft resorption and marginal bone loss around the implants when allograft and xenograft are used.

### Materials & Methods

Sinus bone grafting and implant placement (Osstem, Korea) were performed on 28 patients from September 2003 to January 2006. In group I, a total of 49 implants were placed in 23 maxillary sinus areas of 16 patients together with bone graft using xenograft (Bio-Oss®) and a minimal amount of autogenous bone. In group II, 24 implants were placed in 13 maxillary sinus areas of 12 patients together with bone graft using a minimal amount of autogenous bone and equal amounts of allograft (Regenaform®) and Bio-Oss® in group II.

### Results

Early osseointegration failures of 3 implants in 3 patients (group I: 1 patient, 1 implant; group II: 2 patients, 2 implants) were observed, and revisions were performed for these 3 implant sites, followed by complete prosthodontic treatments. The average height of the remaining alveolar bone before the surgery, immediately after the surgery, and 1 year after the surgery was 4.9 mm, 19.0 mm, and 17.2 mm, respectively, in group I. In group II, the average height of the remaining alveolar bone was 4.0 mm, 19.2 mm, and 17.8 mm before the surgery, immediately after the surgery, and 1 year after the surgery, respectively. The average marginal bone loss 1 year after prosthodontic loading and after 20.8 months' follow-up was 0.6 mm and 0.7 mm, respectively, in group I. A 93.9% success rate was observed for group I, with 3 implants showing bone resorption of >1.5 mm within 1 year of loading. For group II, the average marginal bone loss 1 year after prosthodontic loading and after 19.7 months' follow-up was 0.7 mm and 1.0 mm, respectively. An 83.3% success rate was observed for group II, with 4 implants showing bone resorption of >1.5 mm within 1 year of loading.

### Conclusions

Based on the observations in this study, it was concluded that mixed grafting with demineralized bone matrix for maxillary sinus bone grafting has no significant short-term merit regarding bone healing and stability of implants compared with anorganic bovine bone alone.

Table 1. Marginal bone loss (mm) around the implants

	No. of implants	1 yr loading	Final F/U
Group I	49	0.63 ± 0.51*	0.73 ± 0.52 †
Group II	24	0.68 ± 0.86*	0.98 ± 1.58 †

F/U, Follow-up.

\* P = .725.

† P = .315 (between groups).

Table 2. Comparison in terms of marginal bone loss (mm) 1 year and final follow up after the completion of the upper prosthesis

	No. of implants	1 yr loading	Final F/U
Group I			
Delayed placement	19	0.58 ± 0.57*	0.62 ± 0.54 ‡
Simultaneous placement	30	0.65 ± 0.48*	0.80 ± 0.51 ‡
Group II			
Delayed placement	10	0.38 ± 0.48 †	0.43 ± 0.46 §
Simultaneous placement	14	0.90 ± 1.02 †	1.37 ± 1.96 §

F/U, Follow-up.

\* P .649.

† P .148.

‡ P .255.

§ P .153 (between delayed and simultaneous placement in each group).

## Evaluation of Peri-implant Tissue Response According to the Presence of Keratinized Mucosa

Bum-Soo Kim, Young-Kyun Kim, Pil-Young Yun, Yang-Jin Yi, Hyo-Jeong Lee, Su-Gwan Kim, Jun-Sik Son  
Oral Surg Oral Med Oral Pathol Oral Radiol Endod 2009;107:e24-8

### Objective

The purpose of this study was to evaluate the responses of peri-implant tissue in the presence of keratinized mucosa.

### Materials & Methods

A total of 276 implants were placed in 100 patients. From the time of implant placement, the average follow-up observation period was 13 months. The width of keratinized mucosa was compared and evaluated through the gingival inflammation index (GI), plaque index (PI), the pocket depth, mucosal recession, and marginal bone resorption.

Table 1. Width of keratinized mucosa according to implant systems

	RBM	SLA	Anodizing	Sig.
Width of DKM (mm)	0.64 ± 0.49	0.40 ± 0.50	0.56 ± 0.51	.157
Width of SKM (mm)	3.26 ± 1.40	3.04 ± 1.29	3.19 ± 1.18	.614

DKM, insufficient keratinized mucosa, width 2 mm  
SKM, sufficient keratinized mucosa, width 2 mm  
RBM, Resorbable blasting media (Osstem USII / GSII)  
SLA, sandblasted with large grit and acid-etched (Dentium Implantium)  
Anodizing, Nobel Biocare TiUnite  
other abbreviations as in

Table 2. Crestal bone loss according to implant system

Implant system	Bone loss (mm)	Sig.
Implantium	0.54 ± 0.83	.36
TiUnite	0.44 ± 0.72	
GSII	0.39 ± 0.71	
USII	0.60 ± 0.84	

P > .05

### Results

The GI, PI, and pocket depth in the presence or absence of the keratinized gingiva did not show statistically significant differences. However, mucosal recession and marginal bone resorption experienced statistically significant increases in the group of deficient keratinized mucosa. Based on implant surface treatments, the width of keratinized gingiva and crestal bone loss did not show a significant difference.

### Conclusions

In cases with insufficient keratinized gingiva in the vicinity of implants, the insufficiency does not necessarily mediate adverse effects on the hygiene management and soft tissue health condition. Nonetheless, the risk of the increase of gingival recession and the crestal bone loss is present. Therefore, it is thought that from the aspect of long-term maintenance and management, as well as for the area requiring esthetics, the presence of an appropriate amount of keratinized gingiva is required.

## Morphogenesis of the Peri-Implant Mucosa: A Comparison Between Flap and Flapless Procedures in the Canine Mandible

Tae-Min You, Byung-Ho Choi, Jingxu Li, Feng Xuan, Seung-Mi Jeong, Sun-Ok Jang  
Oral Surg Oral Med Oral Pathol Oral Radiol Endod 2009;107:66-70

### Objective

Although it has been shown that the exclusion of the mucoperiosteal flap can prevent postoperative bone resorption associated with flap elevation, there have been only a few studies on the peri-implant mucosa following flapless implant surgery. The purpose of this study was to compare the morphogenesis of the peri-implant mucosa between flap and flapless implant surgeries by using a canine mandible model.

### Materials & Methods

In six mongrel dogs, bilateral edentulated flat alveolar ridges were created in the mandible. After 3 months of healing, 2 implants were placed in each side by either the flap or the flapless procedure. Three months after implant insertion, the peri-implant mucosa was evaluated by using clinical, radiologic, and histometric parameters, which included the gingival index, bleeding on probing, probing pocket depth, marginal bone loss, and the vertical dimension of the peri-implant tissues.

### Results

The height of the mucosa, length of the junctional epithelium, gingival index, bleeding on probing, probing depth, and marginal bone loss were all significantly greater in the dogs that had the flap procedure than in those that had the flapless procedure ( $p < .05$ ).

### Conclusions

These results indicate that gingival inflammation, the height of junctional epithelium, and bone loss around nonsubmerged implants can be reduced when implants are placed without flap elevation.

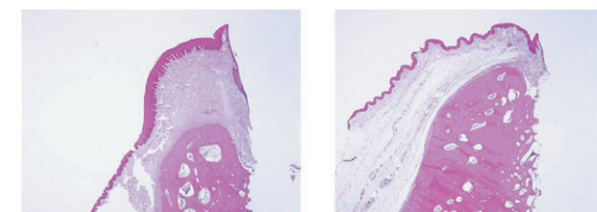


Fig. 1. Magnified view of the specimens showing the peri-implant mucosa. (X 12 magnification).  
A, Implant placed with a flap.  
B, Implant placed without a flap.

Table 1. Parameters of probing depth, gingival index and bleeding on probing around implants when placed with or without a flap

	Flap group	Flapless group	P value
Probing depth (mm)	1.7 ± 0.3	1.0 ± 0.3	.006
Gingival index	0.9 ± 0.5	0	.005
Bleeding on probing	0.7 ± 0.4	0	.005

Table 2. Results of the histometric measurements in both the flap and flapless groups

	Flap group	Flapless group	P value
PM-B (mm)	3.5 ± 0.8	2.2 ± 0.2	.007
PM-aJE (mm)	2.2 ± 0.3	1.2 ± 0.3	.003
aJE-B (mm)	1.3 ± 0.2	1.0 ± 0.2	.018

PM, marginal position of the peri-implant mucosa; B, marginal level of bone-to-implant contact; aJE, apical termination of the junctional epithelium.

## Influence of Premature Exposure of Implants on Early Crestal Bone Loss: An Experimental Study in Dogs

Je-Hyeon Yoo, Byung-Ho Choi, Jingxu Li, Han-Sung Kim, Chang-Yong Ko, Feng Xuan, Seung-Mi Jeong  
Oral Surg Oral Med Oral Pathol Oral Radiol Endod 2008;105:702-6

### Objective

Several studies have reported on spontaneous early exposure of submerged implants, suggesting that exposed implants have greater bone loss than nonexposed implants. The purpose of this study was to compare the effects of implant-abutment connections and partial implant exposure on crestal bone loss around submerged implants.

### Materials & Methods

Bilateral, edentulous, flat alveolar ridges were created in the mandible of 6 mongrel dogs. After 3 months of healing, 2 fixtures were placed on each side of the mandible following a commonly accepted 2-stage surgical protocol. The fixtures on each side were randomly assigned to 1 of 2 procedures. In the first, a cover screw was connected to the fixture, and the incised gingiva was partially removed to expose the cover screw (partially exposed group). In the second, a healing abutment was connected to the fixture so that the coronal portion of the abutment remained exposed to the oral cavity (abutment-connected group). After 8 weeks, micro-computed tomography (micro-CT) at the implantation site was performed to measure the bone height in the peri-implant bone. Data were analyzed by Wilcoxon's signed rank test.

### Results

The average bone height was greater for the abutment-connected fixture ( $9.8 \pm 0.5$  mm) than for the partially exposed fixture ( $9.3 \pm 0.5$  mm;  $p < .05$ ).

### Conclusions

These results suggest that when implant exposure is detected, the placement of healing abutments may help limit bone loss around the submerged implants.

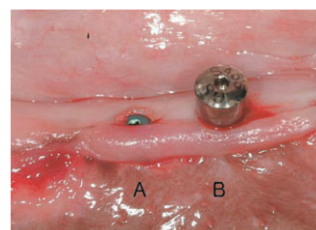


Fig. 1. Clinical features after implant placement. In implant A, a cover screw was connected to the fixture and the incised gingiva was partially removed to expose the implant. In implant B, a healing abutment was connected to the fixture so that the coronal portion of the abutment remained exposed to the oral cavity.

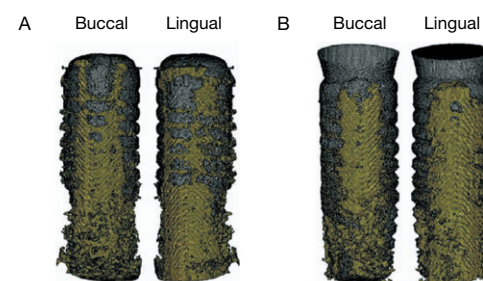


Fig. 2. Three-dimensional micro-CT showing the bone (yellow) around implants (gray). A, Partially exposed implant. B, Abutment-connected implant. Buccal, buccal side of the alveolus; lingual, lingual side of the alveolus.

## Microleakage of Different Sealing Materials in Access Holes of Internal Connection Implant Systems

Sung-Do Park, Yoon Lee, Yu-Lee Kim, Sang-Hui Yu, Ji-Myung Bae, Hye-Won Cho  
J Prosthet Dent 2012(108);173-80

### Objective

The purpose of this study was to evaluate the levels of microleakage through the access holes of screw-retained implant prostheses sealed with different materials.

### Materials & Methods

An implant with an internal hexagonal configuration was connected to a temporary abutment with an acrylic resin crown. The apical 6.5 mm of the access hole was filled with 1 of the following materials: cotton pellet, silicone sealing material, vinyl polysiloxane, or gutta-percha. The remaining coronal 3 mm was sealed with composite resin. Cyclic loading with 21 N at 1 Hz was applied 16 000 times to the specimens in 0.5% basic fuchsin solution according to the long axis of the tooth. Basic fuchsin dye which penetrated into the internal wall of the abutment through the access hole was dissolved with methyl alcohol. Then the absorbance was measured by a spectrophotometer at 540 nm to evaluate the degree of microleakage. The results were statistically analyzed with 1-way ANOVA and the Tukey HSD test.

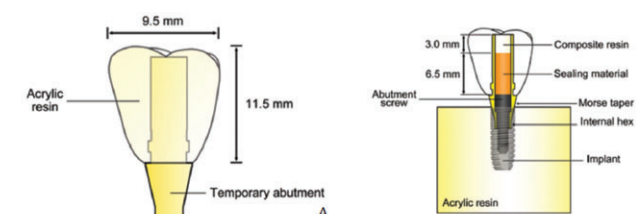


Fig. 1. A, Structure of temporary implant prosthesis. B, Structure of screw-retained implant restoration connected to implant with sealed access hole.

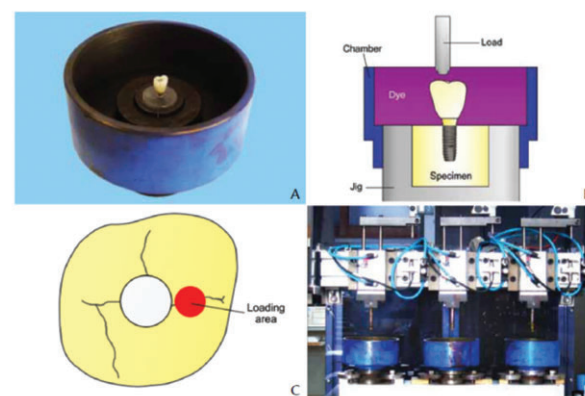


Fig. 2. A, Specimen placed in device of cyclic loading machine. B, Schematic drawing of specimen dipped in dye under loading. C, Location of load on occlusal surface specimen. D, Cyclic loading machine.

### Results

From greatest to least, the levels of microleakage were in the following order: cotton pellet, silicone sealing material, vinyl polysiloxane, and gutta-percha. The microleakage associated with gutta-percha was not significantly different from that of vinyl polysiloxane.

### Conclusions

When sealing the access holes of screw-retained implant prostheses, gutta-percha or vinyl polysiloxane would help reduce microleakage.

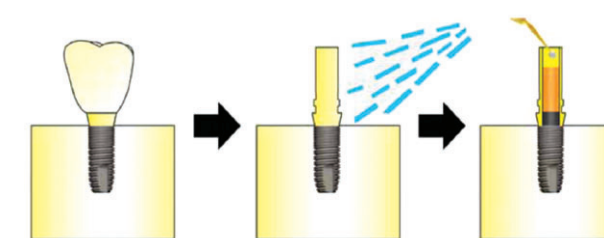


Fig. 3. Process to measure microleakage after cyclic loading

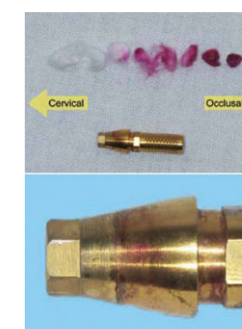


Fig. 4. A, Cotton pellet removed from access hole and temporary abutment in control group. B, Magnified image of cervical neck of temporary abutment.

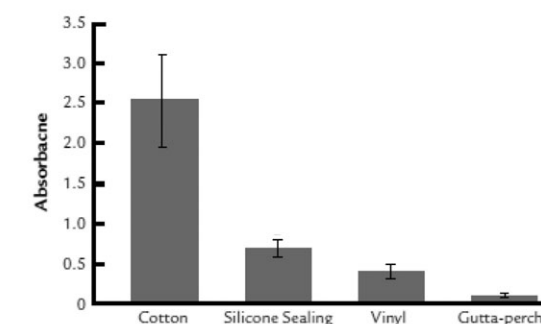


Fig. 5. Average absorbance according to access hole sealing materials.

# Fatigue Characteristics of Five Types of Implant-Abutment Joint Designs

Il-Song Park, Sang-Yong Won, Tae-Sung Bae, Kwang-Yeob Song, Charn-Woon Park, Tae-Gwan Eom, Chang-Mo Jeong  
Met. Mater. Int. 2008;14(2):133-8

## Objective

This study evaluated the fatigue limit of five implant-abutment combinations (Osstem Implant, Korea). The fatigue tests were performed to evaluate the impact of fatigue on the effectiveness of dental implant-abutment assemblies with different joint designs and with different abutment materials, with a special emphasis on the pattern of the dental implant fixture and the abutment, as well as the effect of the abutment material on the stability of the joint area.

## Materials & Methods

Each implant-abutment system (EXTNNTS: USII-TiN Coated, EXANTS: USIII-Safe, EXZRTS: BioTapered Double Thread-ZirAce, INTIWS: GSII-GS Transfer, INTICS: SSI-Solid) was tightened with a closing torque of 32 Ncm. The test specimen was loaded at an incline of 30 degrees toward the loading direction after fixing it 11 mm away from the fixed point. A cyclic compression load was applied at loading cycles of 10 Hz using a hydraulic dynamic testing machine (Model 8516, Instron, USA).

Table 1. Implant systems used in this study

Group	Fixture	Abutment	Screw
EXTNNTS	USII (US2R413)	TiN Coated (CAR535C)	ASR200
EXANTS	USIII (US3R413)	Safe (SFAR542C)	SFSR2S
EXZRTS	Bio Tapered Double Thread (BDT413)	ZioCera (ZAR535)	ASR200
INTIWS	GSII (GS2R4013)	GS Transfer (GSTA5430S)	GSASR
INTICS	SSI (SS1R1813)	Solid (SSS485)	-

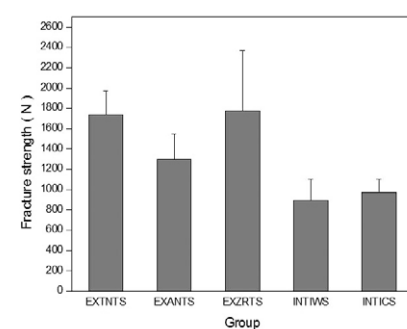


Fig. 1. Static fracture strength of each experimental group.

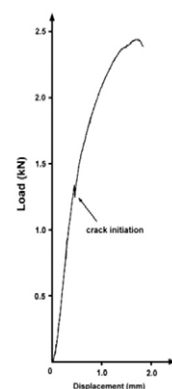


Fig. 2. Load vs displacement curve of EXZRTS group.

## Results & Conclusions

The mean static strength of the EXZRTS group was largest at 1772.2 N and that of the INTIWS group was smallest at 893.8 N. Turkey analysis showed that the group with the abutment joint with the external hexagonal structure pattern had a significantly higher mean static strength than the group with the internal hexagonal structure pattern ( $p < .05$ ). The fatigue limit that guarantees a  $5 \times 10^6$  cycle life according to the condition established by the ISO/FDIS 14801:2003(E) in all experiment groups was shown to be 300-800 N. The fatigue limit that was compared with the static strength was found to be relatively high in the cases with a tapered shape than an external hexagonal shape. In the cases where the shape of the screw joint was an external hexagonal structure, the fatigue limit was relatively higher in cases using the zirconia abutment than the titanium abutment. The fatigue fracture of the zirconia abutment was initiated in the margin with a subsequent sudden unstable fracture.

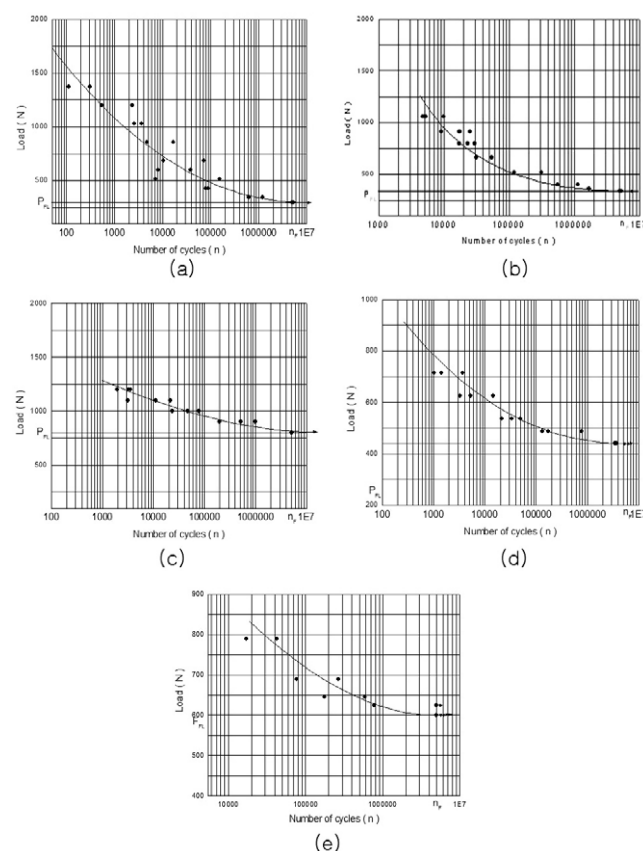


Fig. 3. Fatigue load vs cycles to failure of each experimental group : (a)EXNNTS, (b)EXANTS, (c) EXZRTS, (d) INTIWS, (e) INTICS.

# The Effect of Various Thread Designs on the Initial Stability of Taper Implants

Ju-Hee Park, Yiung-Jun Lim, Myung-Joo Kim, Ho-Beom Kwon  
J Adv. Prosthodont 2009;1:19-25

## Objective

Primary stability at the time of implant placement is related to the level of primary bone contact. The level of bone contact with implant is affected by thread design, surgical procedure and bone quality, etc.

The aim of this study was to compare the initial stability of the various taper implants according to the thread designs, half of which were engaged to inferior cortical wall of type IV bone (Group 1) and the rest of which were not engaged to inferior cortical wall (Group 2) by measuring the implant stability quotient (ISQ) and the removal torque value (RTV).

## Material & Methods

In this study, 6 different implant fixtures with 10 mm length were installed. In order to simulate the sinus inferior wall of type IV bone, one side cortical bone of swine rib was removed. 6 different implants were installed in the same bone block following manufacturer's recommended procedures. Total 10 bone blocks were made for each group. The height of Group 1 bone block was 10 mm for engagement and that of group 2 was 13 mm. The initial stability was measured with ISQ value using Osstell mentor™ and with removal torque using MGT50 torque gauge.




Fig. 1. Characteristics of thread design used in this study.  
A. GSIII (Osstem, Seoul, Korea),  
B. Osseotite NT® (3i, Florida, USA),  
C. Replace® Select (Noble Biocare, Goteborg, Sweden),  
D. Sinus Quick (Neoplast, Seoul, Korea),  
E. USIII (Osstem, Seoul, Korea),  
F. Hexplant (Warantec, Seoul, Korea).

## Results

In this study, we found the following results. 1. In Group 1 with fixtures engaged to the inferior cortical wall, there was no significant difference in RTV and ISQ value among the 6 types of implants. 2. In Group 2 with fixtures not engaged to the inferior cortical wall, there was significant difference in RTV and ISQ value among the 6 types of implants ( $p < .05$ ). There was significant difference in RTV and ISQ value according to whether fixtures were engaged to the inferior cortical wall or not ( $p < .05$ ). 4. Under-drilling made RTV and ISQ value increase significantly in the NT implants which had lower RTV and ISQ value in Group 2 ( $p < .05$ ).

## Conclusions

Without being engaged to the inferior cortical wall fixtures had initial stability affected by implant types. Also in poor quality bone, under-drilling improved initial stability.

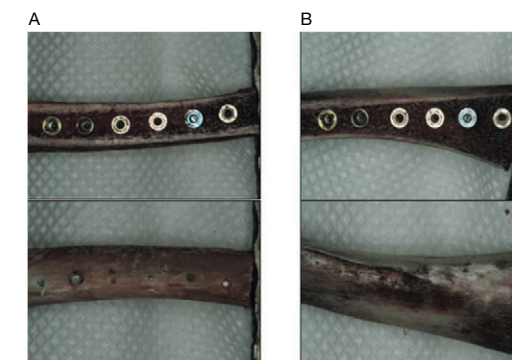


Fig. 2. A. 6 implants were installed with engaging (Group 1).  
B. 6 implants were installed without engaging (Group 2).

## GS SYSTEM References

### Clinical Study

1. Sok-Min Ko, Seong-Jae Park, In-Kyung Lee, A Comparison of the Implant Stability Among the Bone Density Groups: Prospective Study. *J Dent Rehab App Sci.* 2013;29(1):11-21
2. Pil-Young Yun, Young-Kyun Kim. Use of a Buccinator Musculomucosal Flap in Implant Surgery: A Case Report. *Int J Periodontics Restorative Dent.* 2012 Dec;32(6):699-703
3. Jingxu Li, Feng Xuan, Byung-Ho Choi, Seung-Mi Jeong. Minimally invasive ridge augmentation using xenogenous bone blocks in an atrophied posterior mandible: a clinical and histological study. *Implant Dent.* 2013 Apr;22(2):112-6
4. Mi-Ae Jeong, Su-Gwan Kim, Young-Kyun Kim, Hee-Kyun Oh, Yong-Seok Cho, Woo-Cheol Kim, Ji-Su Oh. A Multicenter Prospective Study in Type IV Bone of a Single Type of Implant. *Implant Dent.* 2012 Aug;21(4):330-4
5. Kwang Chung, Chul-Jung Oh, Ji-Won Ha, Min-Suk Kook, Hong-Ju Park, Hee-Kyun Oh, Su-Gwan Kim, Young-Kyun Kim, Woo-Cheol Kim. A multicenter clinical study of installed USII Plus/GSII Osstem implants after bone graft. *Korean Dental Association.* 2012;50(12):743-54
6. Seok-Gyu Kim, Pil-Young Yun, Hyun-Sik Park, June-Sung Shim, Jung-Won Hwang, Young-Kyun Kim. Effect of loading time on the survival rate of anodic oxidized implants: prospective multicenter study. *J Adv Prosthodont;* 2012(4):18-23
7. Yong-Seok Cho, Hyun-Kyung Park, Chang-Joo Park. Bony window repositioning without using a barrier membrane in the lateral approach for maxillary sinus bone grafts: clinical and radiologic results at 6 months. *Clin Oral Implants Res.* 2013 Jun;24(6):618-22
8. Yong-Seok Cho, Kyung-Gyun Hwang, Chang-Joo Park. Postoperative effects of anterior nasal spine bone harvesting on overall nasal shape. *Clin Oral Implants Res.* 2013 Jun;24(6):618-22
9. Seung-Hwan Jeon, Yong-Seok Cho, Byung-Ha Lee, Tae-Yun Im, Kyung-Gyun Hwang, Chang-Joo Park. Evaluation of the feasibility of bony window repositioning without using a barrier membrane in sinus lateral approach. *J Korean Assoc Oral Maxillofac Surg* 2011;37:122-6
10. Hee-Jung Yun, Jung-Chul Park, Jeong-Ho Yun, Ui-Won Jung, Chang-Sung Kim, Seong-Ho Choi, Kyoo-Sung Cho. A short-term clinical study of marginal bone level change around microthreaded and platform-switched implants. *J Periodontal Implant Sci* 2011;41:211-7
11. Jong-Won Jung, Su-Gwan Kim, Seong-Yong Moon, Ji-Su Oh. A Prospective Multicenter Study on the Clinical Success Rate of the Osstem Implant (New GSII RBM) in Edentulous Patients. *Implantology* 2011; 15(2):142-52
12. Min-Jung Kwon, Young-Kyun Kim, In-Sung Yeo, Yang-Jin Yi. Clinical Comparison of Immediately Loaded and Delayed Loaded Osstem GSIII Implant in Partially Edentulous Patients. *J Dent Rehab App Sci.* 2011;27(3):267-75
13. Sang-Woon Moon, Young-Kyun Kim. Analysis of Prognostic Factors after a Variety of Osstem Implant Installation. *Implantology* 2011;15(2):170-9
14. Young-Kyun Kim, Su-Gwan Kim, Jin-Young Park, Yang-Jin Yi, Ji-Hyun Bae. Comparison of Clinical Outcomes of Sinus Bone Graft with Simultaneous Implant Placement: 4-month and 6-month Final Prosthetic Loading. *Oral Surg Oral Med Oral Pathol Oral Radiol Endod.* 2011 Feb;111(2):164-9
15. Young-Kyun Kim, Su-Gwan Kim, Jong-Hwa Kim, Yang-Jin Yi, Pil-Young Yun. Prospective study of tapered resorbable blasting media surface implant stability in the maxillary posterior area. *Oral Surg Oral Med Oral Pathol Oral Radiol.* 2012 Jul;114(1):e19-24
16. Seung-Mi Jeong, Byung-Ho Choi, Ji-Hun Kim, Feng Xuan, Du-Hyeong Lee, Dong-Yub Mo, Chun-Ui Lee. A 1-year Prospective Clinical Study of Soft Tissue Conditions and Marginal Bone Changes around Dental Implants after Flapless Implant Surgery. *Oral Surg Oral Med Oral Pathol Oral Radiol Endod.* 2011 Jan;111(1):41-6
17. Soo-Yeon Kim, Young-Kyun Kim. Short-Term Retrospective Clinical Study of Resorbable Blasting Media Surface Tapered Implants. *J Korean Assoc Maxillofac Plast Reconstr Surg* 2011;33(2):149-53
18. Young-Kyun Kim. Early loading after sinus bone graft and simultaneous implant placement. *Australasian Dental Practice* 2011(March/April): 136-42
19. Bansal J, Kedige S, Bansal A, Anand S. A Relaxed Implant Bed: Implants Placed After Two Weeks of Osteotomy with Immediate Loading - A One Year Clinical Trial. *J Oral Implantol.* 2012 Apr;38(2):155-64
20. Ki-Sung Kim. Impression technique for fabrication of practical implant prosthesis. *The Quintessence.* 2010;15(9):1-10
21. Young-Kyun Kim, Yang-Jin Yi, Su-Gwan Kim, Yong-Seok Cho, Choon-Mo Yang, Po-Chin Liang, Yu-Yal Chen, Lee-Long I, Christopher Sim, Winston Tan, Go Wee Ser, Deng Yue, Man Yi, Gong Ping. Short-term, Multi-center Prospective Clinical Study of Short Implants Measuring Less than 7mm. *J Kor Dent Sci* 2010;3(1):11-6
22. Du-Hyeong Lee, Byung-Ho Choi, Seung-Mi Jeong, Feng Xuan, Ha-Rang Kim. Effects of Flapless Implant Surgery on Soft Tissue Profiles: A Prospective Clinical Study. *Clin Implant Dent Relat Res.* 2011 Dec;13(4):324-9
23. Ji-Hoon Park, Young-Kyun Kim, Winston Tan Kwong Shen, Charlotte Ann Z. Carreon. Evaluation of Survival Rate and Crestal Bone Loss of the Osstem GSII Implant System. *J Kor Dent Sci.* 2009;3(1):30-3
24. Su-Jin Choi, Young-Deok Chee, Se-Wook Koh. Study on Radiographic Evaluation of Marginal Bone Loss around Osseointegrated Implant after Functional Loading. *J Korean Assoc Oral Maxillofac Surg* 2009;35(4):240-7
25. Ji-Hoon Park, Young-Kyun Kim, Pil-Young Yun, Yang-Jin Yi, In-sung Yeo, Hyo-Jung Lee, Jin-Young Park. Analysis of factors affecting crestal bone loss around the implants. *J Kor Dent Sci.* 2009;3(1):12-7
26. Young-Deok Chee, Sang-Chun Oh, Jae-Hwan Lee. Retrospective Study of GSII Implant(Osstem) with an Internal Connection with Microthreads. *J Kor Stomatognathic Function occlusion* 2009;25(4):417-29
27. Young-Kyun Kim, Pil-Young Yun, Su-Gwan Kim, Bum-Soo Kim, Joo L Ong. Evaluation of Sinus Bone Resorption and Marginal Bone Loss after Sinus Bone Grafting and Implant Placement. *Oral Surg Oral Med Oral Pathol Oral Radiol Endod* 2009;107:e21-8
28. Bum-Soo Kim, Young-Kyun Kim, Pil-Young Yun, Yang-Jin Yi, Hyo-Jeong Lee, Su-Gwan Kim, Jun-Sik Son. Evaluation of Peri-implant Tissue Response according to the Presence of Keratinized Mucosa. *Oral Surg Oral Med Oral Pathol Oral Radiol Endod* 2009;107:e24-8
29. Sok-Min Ko, Seung-Il Song, Sung-Jae Park, In-Kyung Lee. Observation of the Change of the Dental Implant Stability and Bone Density Evaluation Methods. *J Korean Acad Periodontol* 2009;39(2):185-92
30. Mi-A Kwon, Yong-Deok Kim, Chang-Mo Jeong, Ju-Youn Lee. Clinical and Radiographic Evaluation of Implants with Dual-microthread: 1-year Study. *J Korean Acad Periodontol* 2009;39(1):27-36
31. Young-Kyun Kim. Evaluation of User Satisfaction about the Tapered Body Implants. *J Korean Clinical Implant* 2009;29(4):367-80
32. Ka-Young Seol, Su-Gwan Kim, Hak-Kyun Kim, Seong-Yong Moon. A Prospective Study of the Multicenter Clinical Study of Osstem Implant (GSII RBM) in Type IV Bone Quality Patients. *Scientific Poster, J Kor Oral Maxillofac Surg* 2009;35(Suppl)
33. Jin-Sung Park, Su-Gwan Kim, Hak-Kyun Kim, Seong-Yong Moon. A Prospective Study of the Multi-facilities Clinical Success Rate of Osstem Implant (GSII RBM) in Edentulous Patient. *Scientific Poster, J Kor Oral Maxillofac Surg* 2009;35(Suppl)
34. Seo-Yoon Kim, Su-Gwan Kim, Hak-Kyun Kim, Seong-Yong Moon. A Prospective Study of the Multi-facilities Clinical Success Rate of Osstem Implant (GSII RBM) in Upper Anterior Teeth after Immediate Extraction. *Scientific Poster, J Kor Oral Maxillofac Surg* 2009;35(Suppl)
35. Du-Hyeong Lee, Seung-Mi Jeong, Byung-Ho Choi. Effects of Flapless Implant Surgery on Soft Tissue Profiles: A Prospective Clinical Study. *Scientific Oral, The 50th Anniversary of KAP, International Prosthodontic Congress & The 6th Biennial Meeting of Asian Academy of Prosthodontics (AAP) 2009*
36. Seong-Yeon Lee, Young-Kyun Kim, Pil-Young Yun, Yang-jin Yi, In-Sung Yeo, Hyo-Jung Lee, Ji-Young Lee. Prospective Clinical Study of Short Implant. *Scientific Poster, 4th Congress of the ICOI Korea* 2009
37. Ji-Hoon Park, Young-Kyun Kim, Pil-Young Yun, Yang-Jin Yi, Hyo-Jeong Lee, Jin-Young Park. Analysis of Factors in Bone Resorption of Peri-implant Crestal Bone. *Scientific Poster, 4th Congress of the ICOI Korea* 2009
38. Moo-Gyung Sung. User Guide of Osstem Implant Systems. *Scientific Oral, The 50th Anniversary of KAP, International Prosthodontic Congress & The 6th Biennial Meeting of Asian Academy of Prosthodontics (AAP) 2009*
39. Young-Kyun Kim, Pil-Young Yun, Jae-Hyung Im. Clinical Retrospective Study of Sinus Bone Graft and Implant Placement. *J Korean Assoc Maxillofac Plast Reconstr Surg* 2008;30(3):294-302
40. Young-Kyun Kim, Pil-Young Yun, Min-Jung Kwon. Short term Retrospective Clinical Study on GSII, SSIII, USIII. *J Korean Implantology(KAOMI)* 2008;12(2):12-22
41. Hye-Rin Joeng, Bo-Ram Byun, Sok-Min Ko, Seung-Il Song. Rehabilitation of Occlusion Using Orthognathic Surgery and Implant Placement in Partially Edentulous Patient with Mandibular Prognathism: Case Report. *J Korean Implantology(KAOMI)* 2008;12(4):48-56
42. Bum-Soo Kim, Young-Kyun Kim, Pil-Young Yun, Yang-Jin Lee. Clinical Evaluation of Sinus Bone Graft Using Allograft and Xenograft. *Scientific Poster, 17th Congress of EAO* 2008
43. Seo-Yoon Kim, Su-Gwan Kim, Hak-Kyun Kim. A Comparison between the Survival Rate of RBM surface implants and Acid-etched surface implants : A prospective 1-year Clinical Study. *Scientific Poster, J Kor Oral Maxillofac Surg* 2008; 34 (Suppl)
44. Heok-Su Choi, Sun-Hee Oh, Jae-Eun Ju, Se-Hoon Kahm, Seok-Koo Kim. Early loading Protocols for Mandibular Implant Overdentures: Case Report. *Scientific Poster, The Korean Academy of Prosthodontics* 2008
45. Su-Jin Choi, Young-Deok Chee, I-Su Jo. Effect of Microthread & Platform Switching on the Maintenance of Marginal Bone Level. *Scientific Poster, 46th Congress of the Korean Assoc Maxillofac Plast Reconstr Surg* 2007
46. Young-Kyun Kim, Pil-Young Yun, Dae-Il Son, Bum-Soo Kim, Jung-Won Hwang. Analysis of Clinical Application of Osstem (Korea) Implant System for 6 Years. *J Korean Implantology(KAOMI)* 2006;10(1):56-65
47. Sun-Hee Oh, Taek-Ga Kwon, Young-Kyun Kim, Jung-Won Hwang. Retrospective Study of Osstem Dental Implants; Clinical and Radiographic Results of 2.5 Years. *Scientific Poster, 15th Congress of EAO* 2006
48. Kyung-Hwan Kwon, Jung-Goo Choi, Seung-Ki Min, Seung-Hwan Oh, Moon-Ki Choi, Jun Lee. GSII Fixture Implant Placement; Review of the Factors Affecting Failure. *Scientific Poster, 45th Congress of the Korean Assoc Maxillofac Plast Reconstr Surg* 2006

## GS SYSTEM References

### Pre-Clinical Study Biology

1. Yee-Seo Kwon, Hee Namgoong, Jung-Hoon Kim, In-Hee Cho, Myung-Duk Kim, Tae-Gwan Eom, Ki-Tae Koo. Effect of microthreads on removal torque and bone-to-implant contact: an experimental study in miniature pigs. *J Periodontal Implant Sci* 2013;43:41-6
2. Du-Hyeong Lee, Byung-Ho Choi, Seung-Mi Jeong, Feng Xuan, Ha-Rang Kim, Dong-Yub Mo. Effects of Soft Tissue Punch Size on the Healing of Peri-implant Tissue in Flapless Implant Surgery. *Oral Surg Oral Med Oral Pathol Oral Radiol Endod* 2010;109:525-30
3. Ha-Rang Kim, Byung-Ho Choi, Feng Xuan, Seung-Mi Jeong. The Use of Autologous Venous Blood for Maxillary Sinus Floor Augmentation in Conjunction with Sinus Membrane Elevation: An Experimental Study. *Clin. Oral Impl. Res.* 2010;21:346-9
4. Tae-Min You, Byung-Ho Choi, Jingxu Li, Feng Xuan, Seung-Mi Jeong, Sun-Ok Jang. Morphogenesis of the Peri-implant Mucosa: A Comparison between Flap and Flapless Procedures in the Canine Mandible. *Oral Surg Oral Med Oral Pathol Oral Radiol Endod* 2009;107:66-70
5. Jung-In Kim, Byung-Ho Choi, Jingxu Li, Feng Xuan, Seung-Mi Jeong. Blood Vessels of the Peri-implant Mucosa: A Comparison between Flap and Flapless Procedures. *Oral Surg Oral Med Oral Pathol Oral Radiol Endod* 2009;107:508-12
6. Seung-Mi Jeong, Byung-Ho Choi, Jingxu Li, Feng Xuan. Simultaneous Flapless Implant Placement and Peri-implant Defect Correction: An Experimental Pilot Study in Dogs. *J Periodontol* 2008;79:876-80
7. Je-Hyeon Yoo, Byung-Ho Choi, Jingxu Li, Han-Sung Kim, Chang-Yong Ko, Feng Xuan, Seung-Mi Jeong. Influence of Premature Exposure of Implants on Early Crestal Bone Loss: An Experimental Study in Dogs. *Oral Surg Oral Med Oral Pathol Oral Radiol Endod* 2008;105:702-6
8. Seung-Mi Jeong, Byung-Ho Choi, Jingxu Li, Feng Xuan. The Effect of Thick Mucosa on Peri-implant Tissues: An Experimental Study in Dogs. *J Periodontol* 2008;79(11):2151-5
9. Chul-Min Park, Su-Gwan Kim, Hak-Kyun Kim, Seong-Yong Moon, Ji-Su Oh, Sung-Mun Baik, Sung-Chul Lim. Effect on the Osteogenesis of Dental Implants after Horizontal Distraction Osteogenesis with Nitrified Distractor. *J Korean Assoc Maxillofac Plast Reconstr Surg* 2008;30(3):225-31
10. Sung-Lim Choi, Jin-Hwan Kim, Dong-Hyeon Hwang, Seung-Ki Min. Effects on Er,Cr:YSGG Laser on Peri-implantitis. *J Korean Assoc Maxillofac Plast Reconstr Surg* 2008;30(5):428-36
11. Jung-Goo Choi, Su-Jin Choi, Seung-Ki Min, Seung-Hwan Oh, Kyung-Hwan Kwon, Min-Ki Choi, June Lee, Se-Ri Oh. Er:YAG Laser Irradiated Implant Surface Observation with Scanning Electron Microscopy. *J Korean Assoc Maxillofac Plast Reconstr Surg* 2008;30(6):540-5
12. Se-Hoon Kahm, Yong-Chul Bae, Seok-Gyu Kim, Je-Uk Park. Determination of Implant Loading Timing in Human: A Pilot Study. Scientific Poster, 17th Congress of EAO 2008
13. Tae-Gwan Eom, In-Hee Cho, Myung-Duk Kim, Young-Seok Cho, Kyoo-Ok Choi. Effects of Final Drill Diameter Size on Bone Formation in the Mandible of Micropig. Scientific Poster, 17th Congress of EAO 2008
14. Soo-Young Bae, Su-Kyoung Kim, Eun-Jung Kang, Young-Bae An, Gyu-Sub Eom, Tae-Gwan Eom. The Effect of Hydroxyapatite-blasted Titanium Surface Roughness on Osteoblast-like Cell Line MG-63. Scientific Poster, Meeting of the Korean Society for Biomaterials 2008
15. Jae-Wan Park, Min-Suk Kook, Hong-Ju Park, Uttom Kumar Shet, Choong-Ho Choi, Suk-Jin Hong, Hee-Kyun Oh. Comparative Study of Removal Effect on Artificial Plaque from RBM Treated Implant. *J Korean Assoc Maxillofac Plast Reconstr Surg* 2007;29(4):309-20
16. Su-Yeon Cho, Hye-Ran Jeon, Sun-Kyoung Lee, Seoung-Ho Lee, Jun-Young Lee, Keum-Ah Han. The Effect of Ca-P Coated Bovine Mineral on Bone Regeneration around Dental Implant in Dogs. *J Korean Acad Periodontol* 2006;36(4):913-23
17. Pil-Kwy Jo, Seung-Ki Min, Kyung-Hwan Kwon, Young-Jo Kim. Scanning Electron Microscopic Study of Implant Surface after Er,Cr:YSGG Laser Irradiation. *J Korean Assoc Maxillofac Plast Reconstr Surg* 2006;28(5):454-69

### Pre-Clinical Study Biomechanics

1. Sung-Do Park, Yoon Lee, Yu-Lee Kim, Sang-Hui Yu, Ji-Myung Bae, Hye-Won Cho. Microleakage of different sealing materials in access holes of internal connection implant systems. *J Prosthet Dent* 2012(108):173-80
2. Ki-Seong Kim, Young-Jun Lim, Myung-Joo Kim, Ho-Beom Kwon, Jae-Ho Yang, Jai-Bong Lee, Soon-Ho Yim. Variation in the Total Lengths of Abutment/Implant Assemblies Generated with a Function of Applied Tightening Torque in External and Internal Implant-Abutment Connection. *Clin. Oral Impl. Res.* 2011;22:834-9
3. Tae-Gwan Eom, Seung-Woo Suh, Myung-Duk Kim, Young-Kyun Kim, Seok-Gyu Kim. Influence of Implant Length and Insertion Depth on Stress Analysis: a Finite Element Study. Scientific Poster, Academy of KSME 2011
4. Si-Hoon Jo, Kyoung-Il Kim, Jae-Min Seo, Kwang-Yeob Song, Ju-Mi Park, Seung-Geun Ahn. Effect of Impression Coping and Implant Angulation on the Accuracy of Implant Impressions: An in Vitro Study. *J Adv Prosthodont.* 2010;2(4):128-33

5. Jae-Myoung Cho, Uk Cho, Mi-Jung Yun, Chang-Mo Jeong, Young-Chan Jeon. Influence of Implant Diameter and Length Changes on Initial Stability. *J Kor Acad Prosthodont* 2009;47:335-41
6. Duck-Rae Kim, Myung-Joo Kim, Ho-Beom Kwon, Seok-Hyung Lee, Young-Jun Lim. In Vitro Study on the Initial Stability of Two Tapered Dental Implant Systems in Poor Bone Quality. *J Korean Acad Stomatog Func Occ.* 2009;25(4):389-99
7. Sung-Ae Shin, Chang-Seop Kim, Wook Cho, Chang-Mo Jeong, Young-Chan Jeon, Ji-Hoon Yoon. Mechanical Strength of Zirconia Abutment in Implant Restoration. *J Korean Acad Stomatog Func Occ.* 2009;25(4):347-58
8. Ju-Hee Park, Yiung-Jun Lim, Myung-Joo Kim, Ho-Beom Kwon. The Effect of Various Thread Designs on the Initial Stability of Taper Implants. *J Adv. Prosthodont* 2009;1:19-25
9. Mi-Soon Lee, Kyu-Won Suh, Jae-Jun Ryu. Screw Joint Stability under Cyclic Loading of Zirconia Implant Abutments. *J Kor Acad Prosthodont* 2009;47(2):164-73
10. Il-Song Park, Sang-Yong Won, Tae-Sung Bae, Kwang-Yeob Song, Charn-Woon Park, Tae-Gwan Eom, Chang-Mo Jeong. Fatigue Characteristics of Five Types of Implant-Abutment Joint Designs. *Met. Mater. Int.* 2008;14(2):133-8
11. Hyon-Mo Shin, Chang-Mo Jeong, Yonung-Chan Jeon, Mi-Jeong Yeun, Ji-Hoon Yoon. Influence of Tightening Torque on Implant-Abutment Screw Joint Stability. *J Kor Acad Prosthodont* 2008;46(4):396-408
12. Chun-Yeo Ha, Chang-Whe Kim, Young-Jun Lim, Myung-Joo Kim. Effect of Casting Procedure on Screw Loosening of UCLA Abutment in Two Implant-Abutment Connection Systems. *J Kor Acad Prosthodont* 2008;46(3):246-54
13. Jae-Kyoung Park, Chang-Mo Jeong, Young-Chan Jeon, Ji-Hoon Yoon. Influence of Tungsten Carbide/Carbon Coating of Implant-Abutment Screw on Screw Loosening. *J Kor Acad Prosthodont* 2008;46(2):137-47
14. Tae-Sik Lee, Jung-Suk Han, Jae-Ho Yang, Jae-Bong Lee, Sung-Hun Kim. The Assessment of Abutment Screw Stability Between the External and Internal Hexagonal Joint under Cyclic Loading. *J Kor Acad Prosthodont* 2008;46(6):561-8
15. Jae-Myoung Cho, Chang-Mo Jeong, Yonung-Chan Jeon, Mi-Jeong Yeun. The Influence of Diameter and Length on Initial Stability in Implant with Similar Surface Area : An Experimental Study. Scientific Poster, J Kor Acad Prosthodont 2008 Conference
16. Chun-Yeo Ha, Chang-Whe Kim, Young-Jun Lim, Myung-Joo Kim, Ho-Bum Kwon. The Influence of Abutment Angulation on Screw Loosening of Implant in the Anterior Maxilla. Scientific Poster, J Kor Acad Prosthodont 2008 Conference
17. Si-Yeob Kim, Byung-kook Kim, Jin-Ho Heo, Ju-Youn Lee, Chang-Mo Jeong, Yong-Deok Kim. Evaluation of Stability of Double Threaded Implant-Emphasis on Initial Stability Using Osstell MentorTM; Part I. *J Kor Acad Stomatog Func Occlusion* 2007;23(4)
18. Seung-woo Suh, Myung-Duk Kim, Tae-Gwan Eom. The Effect of Various Taper Angles of the Internal Morse Taper Connection Type Dental Implant Fixture on Their Stress Distribution by FEA Study. Scientific Poster, 16th Congress of EAO 2007
19. Han-Su Kim, Hee-Jung Kim, Chae-Heon Chung. Detorque Force of TiN-Coated Abutment Screw with Various Coating Thickness after Repeated Closing and Opening. *J Kor Acad Prosthodont* 2007;45(6):769-79
20. Chae-Heon Chung. Detorque Force of TiN-coating Abutment Screw with Various Coating Thickness After Repeated Closing and Opening. Scientific Oral, 12th International College of Prosthodontists Meeting, 2007
21. Gap-Yong Oh, Sung-Hwa Park, Seok-Gyu Kim. Influence of Implant Fixture Design on Implant Primary Stability. *J Kor Acad Prosthodont* 2006;45(1):98-106
22. Jin-Uk Choi, Chang-Mo Jeong, Young-Chan Jeon, Jang-Seop Lim, Hee-Chan Jeong, Tae-Gwan Eom. Influence of Tungsten Carbide/Carbon on the Preload of Implant Abutment Screws. *J Kor Acad Prosthodont* 2006;44(2):229-42
23. Mun-Ji Hyun, Cheol-Won Lee, Mok-Kyun Choie. The Effect of Implant Abutment Length, Surface and Cement Type on the Prosthesis Retention. Scientific Poster, 15th Congress of EAO 2006
24. Yong-Suk Cho, Chul-Hyun Jeong, Tae-Soo Kim, Dong-Hoon Jang, Tae-Gwan Eom. Temperature Measurement During Implant-Site Preparation. Scientific Poster, 15th Congress of EAO 2006
25. Ji-Hoon Yoon, Sung-Geun Lee, Chang-Mo Jeong, Tae-Gwan Eom. The Study of Dynamic Behaviour about Implant System with WC/C Coating. Scientific Poster, 15th Congress of EAO 2006
26. Ji-Hoon Yoon, Kim KH, Eom SH, Chang-Mo Jeong, Tae-Gwan Eom, Gyeo-Rok Jeon. A Comparative Analysis of the Accuracy of Implant Techniques. Scientific Poster, 15th Congress of EAO 2006
27. Kwang-Hoon Kim, Chang-Mo Jeong, Ji-Hoon Yoon, Ji-Yun Seong. Effect of Implant-Abutment Joint Design on Dynamic Fatigue Strength. Scientific Poster, 20th Congress of AO 2005
28. Kwang-Hoon Kim, Chang-Mo Jeong, Ji-Hoon Yoon. The Effect of WC(Tungsten-Carbide) Coating for Abutment Screw on Reliability of Connection. Scientific Poster, 14th Congress of EAO 2005
29. Tae-Gwan Eom, Chang-Mo Jeong, Kwang-Hoon Kim. The Effect of Tightening Torque on Reliability of Joint Stability. Scientific Poster, 14th Congress of EAO 2005

## A Comparison of Implant Stability Quotients Measured Using Magnetic Resonance Frequency Analysis from Two Directions: Prospective Clinical Study During the Initial Healing Period

Jong-Chul Park, Hyun-Duck Kim, Soung-Min Kim, Myung-Jin Kim, Jong-Ho Lee  
Clin Oral Impl Res 2010;21(6):591-7

### Objective

Given that the orientation of the transducer (mesiodistal or buccolingual) affects the data obtained from a piezoelectric resonance frequency analysis (RFA), this study evaluated whether it is necessary to use measurements taken in two different directions (mesiodistal and buccolingual) when using magnetic RFA to assess changes in the stiffness of dental implants.

### Materials & Methods

A prospective clinical trial was completed, in a total of 53 patients, on 71 non-submerged dental implants that were inserted to replace the unilateral loss of mandibular molars. All of the implants were of the same diameter (4.1 mm), length (10 mm), and collar height (2.8 mm). The implant stability quotient (ISQ) was measured during the surgical procedure, and at 4 and 10 weeks after surgery. Measurements were taken twice in each direction: in the buccolingual direction from the buccal side and in the mesiodistal direction from the mesial side. The average of two measurements in each direction was regarded as the representative ISQ of that direction. The higher and lower values of the two ISQs (buccolingual and mesiodistal) were also classified separately. In addition, the variation in ISQ was quantified by subtracting the lower value from the higher value, and the implants were classified into two groups according to this variation: one with ISQ variation of 3 or more and the other with a variation of <3.

Table 1. The change in implant stability quotient (ISQ) discrepancy measured from two different directions at each measurement time point

Diameter	ISQ discrepancy* (mean SD)	P-value**
Straumann (N=25)	1.1 ± 2.72	0.16
During surgery	0.42 ± 1.48	
Osstem SSII (N=28)	0.36 ± 3.6	0.317
During surgery	-0.14 ± 1.54	
At post-operative week 10		

\* ISQ discrepancies were calculated by subtracting the BL from the MD at each time point.  
\*\* P-values were calculated for differences between two time points (during surgery and at postoperative week 10) using a Wilcoxon's signed-ranks test.

### Results

There were no differences between the two ISQs when measured from different directions, but there were significant differences between the higher and lower values of the ISQs at each measurement point. A significant difference was also observed between the two ISQ variation groups in the pattern of change of the lower value for the period from immediately after surgery to 10 weeks after surgery.

### Conclusions

Acquisition of two directional measurements and classification of the higher and lower values of the two directional ISQs may allow clinicians to detect patterns of change in ISQ that would not be identified if only one directional measurement were made.

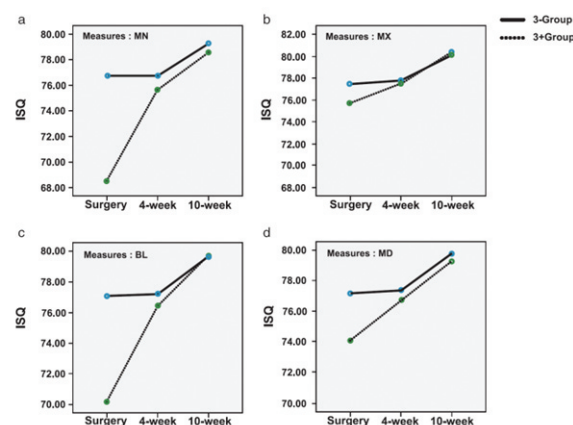


Fig. 1. The comparison of the pattern of change in the implant stability quotient (ISQs) obtained from the four measures from surgery to 10 weeks after surgery.  
3+Group—the group with ISQ variation of 3 or more.  
<3-Group, the group with ISQ variation of <3.  
(a) Pattern of change of MN.  
(b) Pattern of change of MX.  
(c) Pattern of change of BL.  
(d) Pattern of change of MD.

## Non-Submerged Type Implant Stability Analysis During Initial Healing Period by Resonance Frequency Analysis

Deug-Han Kim, Eun-Kyoung Pang, Chang-Sung Kim, Seong-Ho Choi, Kyoo-Sung Cho  
J Korean Acad Periodontol 2009;39(3):339-48

### Objective

The purpose of the present study was to analyze the implant stability quotient (ISQ) values for Korean non-submerged type implant and determine the factors that affect implant stability.

### Materials & Methods

A total of 49 Korean non-submerged type implants were installed in 24 patients, and their stability was measured by resonance frequency analysis (RFA) at the time of surgery, and 1, 2, 3, 4, 8, 12 weeks postoperatively. The data for implant site, age, sex, implant length and diameter, graft performing, bone type, and insertion torque were analyzed.

### Results

The lowest mean stability measurement was at 3 weeks. There was significant difference between implant placement and 12 weeks. There was significant difference between implant placement and 12 weeks in diameters of 4.1 mm and 4.8 mm. Also, there were significant differences between diameters of 4.1 mm and 4.8 mm at implant placement and 12 weeks after surgery. This result suggests that the factor related to implant diameter may affect the level of implant stability. No statistically significant relationship was found between the resonance frequency analysis and the variables of maxilla/mandible, sex, anterior/posterior, implant length, age of patient, graft performing, bone type, insertion torque during initial healing period.

### Conclusions

These findings suggest that the factor related to implant diameter may affect the variance of implant stability, and ISQ value of implant was stable enough for proved stability level during initial healing period.

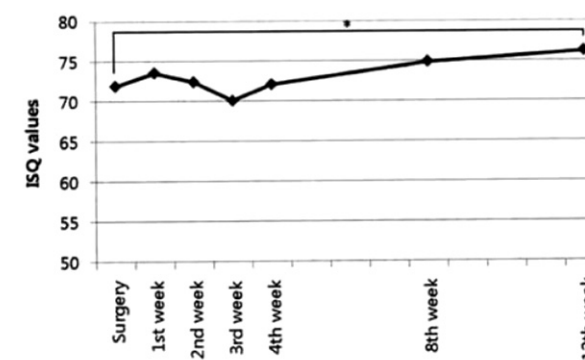


Fig. 1. Change in the mean ISQ values during healing up to 12 weeks.  
\*: Statistically significant change compared to surgery (P < 0.05)

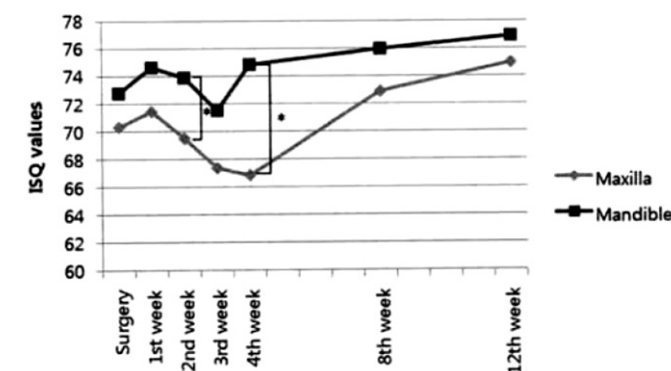


Fig. 2. Evaluation of implant stability between implant placement and 12 weeks for implant placed in the maxilla and in the mandible.  
\*: Statistically significant difference between maxilla and mandible (P < 0.05)

Table 1. Statistical Rate of Change Date for ISQ Values for Different Variables

Variable	P value	Significance
Diameter		
Maxilla/Mandible	0.6141	> 0.05
Sex	0.9918	> 0.05
Anterior/Posterior	0.8408	> 0.05
Length	0.6317	> 0.05
Diameter	0.0092	< 0.05
Age	0.3836	> 0.05
Graft	0.9635	> 0.05
Bone type	0.8354	> 0.05
Insertion torque	0.0675	> 0.05

\*: Statistically significant effective factor for rate of change between surgery and 3 months (P < 0.05)



## Evaluation of Peri-Implant Tissue in Nonsubmerged Dental Implants: A Multicenter Retrospective Study

Young-Kyun Kim, Su-Gwan Kim, Hee-Kyun Oh, Yong-Geun Choi, Yong-Seok Cho, Young-Hak Oh, Jun-Sik Son  
 Oral Surg Oral Med Oral Pathol Oral Radiol Endod. 2009;108(2):189-95

### Objective

The objective of this study was to evaluate the peri-implant's hard and soft tissue response associated with the 1-stage, nonsubmerged, endosseous dental implant.

### Materials & Methods

A multicenter retrospective clinical evaluation was performed on 339 nonsubmerged implants placed in 108 patients at 5 clinical centers between January 2003 and December 2007.

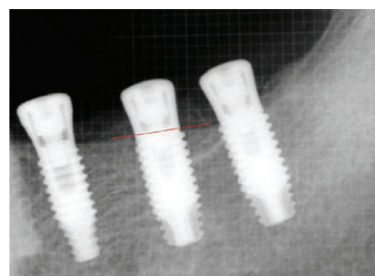


Fig. 1. Periapical radiograph taken immediately after implant placement. In the #36 area, an implant, 4.8 mm in diameter and 10 mm in length, was placed. The crestal bone level in the vicinity of implant was considered as the baseline.

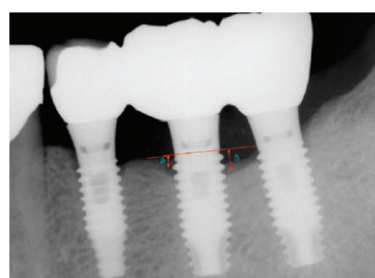


Fig. 2. Periapical radiograph taken 1 year after implant placement. Based on the baseline, the crestal bone level on the radiograph taken immediately after surgery, from mesial side (a) and distal side (b), the vertical length to the first implant-bone contact area was measured and added by referring to the magnification rate and 0.8 mm pitch, and the average was obtained. In this case, a=0.8 mm and b=1.2 mm, and after 1 year; the mean amount of crestal bone resorption was 1.2 mm.

### Results

After a mean follow-up period of 30 months, the mean crestal bone resorption in 339 implants was 0.43 mm. The survival and success rates were observed to be 99.1% and 95.1%, respectively. The mean calculus, inflammatory, and plaque indices were 0.13, 0.37, and 0.73, respectively, and the mean width of buccal keratinized mucosa was observed to be 2.43 mm.

### Conclusions

The short- to intermediate-term evaluation of the 1-stage, nonsubmerged, endosseous implant yields relatively high survival and success rates.

Table 1. Crestal bone resorption

Bone resorption	No. of implants
None	198
0.1-0.5 mm	10
0.6-1.0 mm	81
1.1-2.0 mm	7
>2.0 mm	8
Total	304*

\*Not specified for 35 implants.

Table 2. Implant failure and survival by year

Year	No. implants at start of year	No. implants survival at follow-up	Failures	Survival, %
1	339	336	3	99.1
2	336	336	0	100
3	336	336	0	100

## A Randomized Clinical 1-year Trial Comparing Two Types of Non-Submerged Dental Implant

Jong-Chul Park, Seung-Ryong Ha, Soung-Min Kim, Myung-Jin Kim, Jai-Bong Lee, Jong-Ho Lee  
 Clin Oral Implants Res 2010 Feb;21(2):228-36

### Objective

This study compared the implant stability and clinical outcomes obtained with two types of non-submerged dental implant that have different thread designs and surface treatments.

### Materials & Methods

A randomized clinical trial with one year of follow-up was performed on 56 participants with 75 implants (control group, 36 implants in 28 subjects; experimental group, 39 implants in 28 subjects). The experimental group received the Osstem SSII Implant system; the control group received the Standard Straumann® Dental Implant System. The diameter and length of the fixture were uniform at 4.1 mm and 10 mm and all the implants restored the unilateral loss of one or two molars from the mandible. To compare implant stability, the peak insertion torque, implant stability quotient (ISQ), and periosteal value (PTV) were evaluated during surgery, and at 4 and 10 weeks after surgery. To compare marginal bone loss, standard periapical radiographs were obtained during surgery, and at 10 weeks and one year after surgery.

### Results

This study showed statistically significant differences between the two groups in peak insertion torque ( $p = .009$ ) and ISQ ( $p = .003$ ) but not in PTV ( $p = .097$ ) at surgery. In contrast, there was no statistically significant difference in the pattern of change of ISQ during the 10 weeks after surgery ( $p = .339$ ). For marginal bone loss, no significant difference was observed between the control and experimental groups before functional loading ( $p = .624$ ), but after one year of follow-up, a borderline difference was noted ( $p = .048$ ).

### Conclusions

The success rate after one year of follow-up was 100% for both systems of implant, despite there being significant difference in implant stability during surgery. There was a borderline difference in marginal bone loss after one year of follow-up.

Table 1. Comparison of marginal bone loss between the two implants

Duration	Area †	Type of Implant				p value*
		Standard Straumann® Dental Implant system		Osstem SSII Implant system		
		N	Mean ± SD (mm)	N	Mean ± SD (mm)	
During the 10 weeks after surgery	Proximal	25	0.96 ± 0.64	28	0.75 ± 0.49	.273
	Distal	25	0.62 ± 0.44	28	0.60 ± 0.51	.722
	Avg ‡	25	0.79 ± 0.51	28	0.67 ± 0.43	.624
One year follow-up	Proximal	24	1.21 ± 0.57	26	0.92 ± 0.68	.066
	Distal	24	0.93 ± 0.39	26	0.65 ± 0.37	.013
	Avg	24	1.07 ± 0.46	26	0.79 ± 0.42	.048

\* The p values were calculated using Mann - Whitney test.

† Area means the radiographic measurement area for calculation of marginal bone loss.

‡ Avg means the average value of proximal and distal bone loss.

## Four-Year Survival Rate of RBM Surface Internal Connection Non-Submerged Implants and the Change of the Peri-Implant Crestal Bone

Hye-Ran Jeon, Myung-Rae Kim, Dong-Hyun Lee, Jung-Sub Shin, Na-ra Kang  
J Korean Assoc Maxillofac Plast Reconstr Surg 2009;31(3):237-42

Implant-supported fixed and removable prostheses provide a proper treatment modality with reliable success. The SSII implants is a one-stage nonsubmerged threaded titanium implants with Resorbable Blasting Media (RBM) surface developed by Osstem implant (Seoul, Korea) in October of 2002.

This study is to evaluate the survival rate of the SSII implants for 4 years using radiographic parameters and to review the retrieved implants by the cytotoxicity tests.

Since September 2003, 439 SSII implants had been used for 173 patients at Ewha Women University Medical Center in Korea. Patients consisted of 91 females (52.6 %) and 82 males (47.4 %). The patients' mean age was  $42 \pm 16$  years, ranging from 21 to 83 years. The follow-up period ranged from 9 to 46 months (mean F/U  $24.2 \pm 10.2$  months).

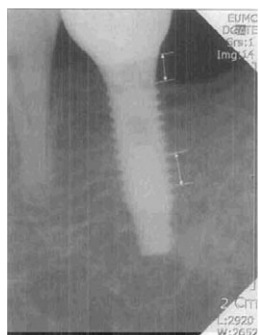

Fig. 1. A computer-assisted calibration was carried out for each single site by evaluating the given distance between several threads (pitch: 0.8 mm).

The results are as follows:

1. Of 439 implants, 17 implants were removed and 4-year cumulative survival rate was 96.1%.
2. 82.3% of 17 failed implants were founded during healing phase, and 94.1% of failed fixtures were removed within 5 months after implantation.
3. Crestal bone around the implants was resorbed to 1mm in 89.0%, to 1-2 mm loss of the marginal bone in 8.3%, and the bone loss over 2 mm was occurred in 2.7%.
4. Microscopic examination of the retrieved implants disclosed Grade 0 cytotoxicity in 4 and Grade 1 cytotoxicity in 2 of 6 groups divided according to lot numbers. Inhibition rate with optical density was acceptable as low as ISO standard.

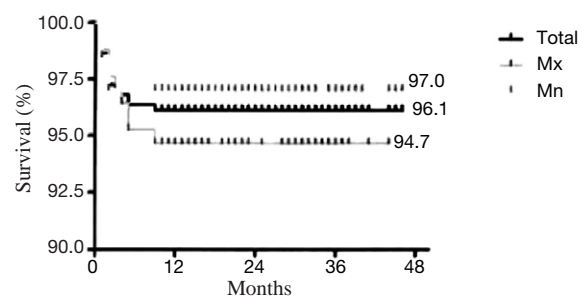


Fig. 2. The 4-year cumulative survival rate: ( $p > .05$ ).

## Influence of Abutment Connections and Plaque Control on the Initial Healing of Prematurely Exposed Implants: An Experimental Study in Dogs

Seung-Mi Jeong, Byung-Ho Choi, Jingxu Li, Han-Sung Kim, Chang-Yong Ko, Seoung-Ho Lee  
J Periodontol 2008;79:1070-4

### Objective

Spontaneous early implant exposure is believed to be harmful, resulting in early crestal bone loss around submerged implants. The purpose of this study was to examine the influence of abutment connections and plaque control on the initial healing of prematurely exposed implants in the canine mandible.

### Material & Methods

Bilateral, edentulated, flat alveolar ridges were created in the mandible of 10 mongrel dogs. After 3 months of healing, two implants were placed on each side of the mandible following a commonly used two-stage surgical protocol. Implants on each side were randomly assigned to one of two procedures: 1) connection of a cover screw to the implant and removal of the gingiva to expose the cover screw; and 2) connection of a healing abutment to the implant so that the coronal portion of the abutment remained exposed to the oral cavity. In five dogs (plaque control group), meticulous plaque control was performed. In the other five dogs (no plaque control group), plaque was allowed to accumulate. At 8 weeks post-implantation, microcomputed tomography was performed at the implantation site to measure bone height in the peri-implant bone.

### Results

The plaque control group had greater vertical alveolar ridge height ( $9.7 \pm 0.5$  mm) than the group without plaque control ( $7.4 \pm 0.7$  mm;  $p < .05$ ). In the plaque control group, the average bone height was greater with the abutment-connected implant ( $10.1 \pm 0.5$  mm) than with the partially exposed implant ( $9.3 \pm 0.5$  mm;  $p < .05$ ). In the group without plaque control, the average bone height was greater with the partially exposed implant ( $8.2 \pm 0.6$  mm) than with the abutment-connected implant ( $6.5 \pm 0.7$  mm;  $p < .05$ ).

### Conclusions

These results suggest that the placement of healing abutments and meticulous plaque control may limit bone loss around submerged implants when implants are partially exposed.

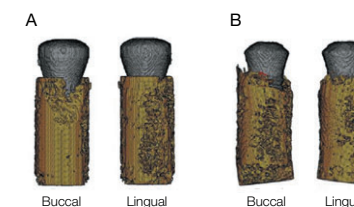


Fig. 1. A) Three-dimensional micro-CT of an abutment-connected implant from the plaque control group demonstrating bone (yellow) around the implants (gray). B) Three-dimensional micro-CT of a partially exposed implant from the plaque control group demonstrating bone (yellow) around the implants (gray).

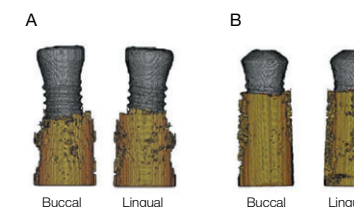


Fig. 2. A) Three-dimensional micro-CT of an abutment-connected implant from the group without plaque control demonstrating bone (yellow) around the implants (gray). B) Three-dimensional micro-CT of a partially exposed implant from the group without plaque control demonstrating bone (yellow) around the implants (gray).

Table 1. Parameters (mm; mean  $\pm$  SD) of bone height during the healing period in abutment-connected and partially exposed dental implant groups

	Abutment-connected sites	Partially exposed sites	P values
Plaque control	$10.1 \pm 0.5$	$9.3 \pm 0.5$	$< .05$
No plaque control	$6.5 \pm 0.7$	$8.2 \pm 0.6$	$< .05$

## Peri-Implant Bone Reactions at Delayed and Immediately Loaded Implants: An Experimental Study

Se-Hoon Kim, Byung-Ho Choi, Jingxu Li, Han-Sung Kim, Chang-Yong Ko, Seung-Mi Jeong, Feng Xuan, Seoung-Ho Lee  
Oral Surg Oral Med Oral Pathol Oral Radiol Endod 2008;105:144-8

### Objective

The aim of this study was to compare the peri-implant bone reactions of implants subjected to immediate loading with those subjected to delayed loading.

### Materials & Methods

In 6 mongrel dogs, bilateral edentulated flat alveolar ridges were created in the mandible. After 3 months of healing, 1 implant was placed in each side. On one side of the mandible, the implant was loaded immediately with a force of 20N that was applied at a 120° angle from the tooth's longitudinal axis at the labial surface of the crown for 1,800 cycles per day for 10 weeks. On the opposite side, after a delay of 3 months to allow osseointegration to take place, the implant was loaded with the same force used for the immediately loaded implant. Ten weeks after loading, microscopic computerized tomography at the implantation site was performed. Osseointegration was calculated as the percentage of implant surface in contact with bone. Bone height was measured in the peri-implant bone.

### Results

The mean osseointegration was greater (65.5%) for the delayed-loading implants than for the immediately loaded implants (60.9%;  $p < .05$ ). The mean peri-implant bone height was greater (10.6 mm) for the delayed-loading implants than for the immediately loaded implants (9.6 mm;  $p < .05$ ).

### Conclusions

The results indicate that when implants are immediately loaded, the immediate loading may decrease both osseointegration of dental implants and bone height.

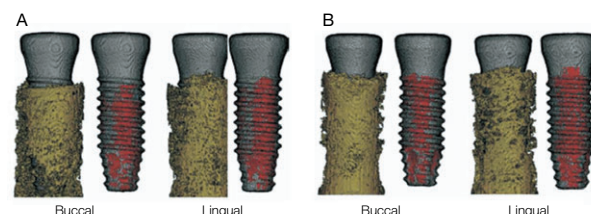


Fig. 1. Three-dimensional micro-CT showing the bone (yellow) and the bone-to-implant contact area (red) around the implants (gray): A, immediately loaded implant; B, delayed loading implant. Buccal, buccal side of the alveolus; lingual, lingual side of the alveolus.

Table 1. Parameters (mean values and standard deviations) of bone-to-implant contact and bone height around dental implants with either immediate or delayed loading

	Immediately	Delayed	P values
Bone-implant contact (%)	60.9 ± 8.2	65.5 ± 8.8	< .05
Bone height (mm)	9.6 ± 0.5	10.6 ± 0.4	< .05

## Flapless Implant Surgery: An Experimental Study

Seung-Mi Jeong, Byung-Ho Choi, Jingxu Li, Han-Sung Kim, Chang-Yong Ko, Jae-Hyung Jung, Hyeon-Jung Lee, Seoung-Ho Lee, Wilfried Engelke  
Oral Surg Oral Med Oral Pathol Oral Radiol Endod 2007;104:24-8

### Objective

The purpose of this study was to examine the effect of flapless implant surgery on crestal bone loss and osseointegration in a canine mandible model.

### Materials & Methods

In 6 mongrel dogs, bilateral, edentulated, flat alveolar ridges were created in the mandible. After 3 months of healing, 2 implants in each side were placed by either flap or flapless procedures. After a healing period of 8 weeks, microcomputerized tomography at the implantation site was performed. Osseointegration was calculated as percentage of implant surface in contact with bone. Additionally, bone height was measured in the peri-implant bone.

### Results

The mean osseointegration was greater at flapless sites (70.4%) than at sites with flaps (59.5%) ( $p < .05$ ). The mean peri-implant bone height was greater at flapless sites (10.1 mm) than at sites with flaps (9.0 mm) ( $p < .05$ ).

### Conclusions

Flapless surgery can achieve results superior to surgery with reflected flaps. The specific improvements of this technique include enhanced osseointegration of dental implants and increased bone height.

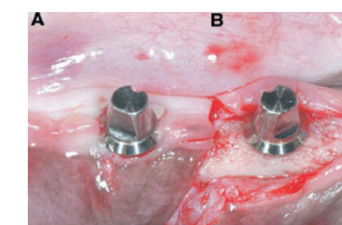


Fig. 1. Clinical feature after implant placement. A: Flapless surgery; B: Flap surgery.

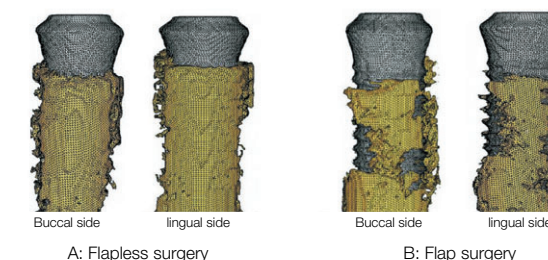


Fig. 2. Three-dimensional micro-CT showing the bone (yellow) around the implants (gray). A: Flapless surgery; B: Flap surgery.

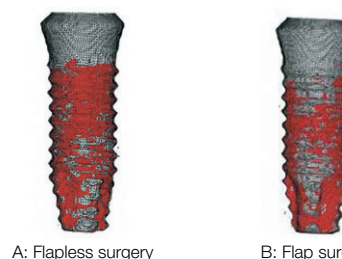


Fig. 3. Three-dimensional micro-CT overview of the bone-to-implant contact area (red) around the implant surface (gray). A: Flapless surgery; B: Flap surgery.

Table 1. Parameters of bone-to-implant contact and bone height around dental implants when placed either without or with a flap

	Flapless group	Flap group
Bone-implant contact (%)	70.4 ± 6.3	59.5 ± 6.3
Bone height (mm)	10.1 ± 0.5	9.0 ± 0.7

# The Effect of Internal Implant-Abutment Connection and Diameter on Screw Loosening

Chun-Yeo Ha, Chang-Whe Kim, Young-Jun Lim, Kyung-Soo Jang  
J Kor Acad Prosthodont 2005;43(3):379-92

## Objective

One of the common problems of dental implant prosthesis is the loosening of the screw that connects each component, and this problem is more common in single implant-supported prostheses with external connection and in molars.

The purposes of this study were:

(1) to compare the initial abutment screw de torque values of the six different implant-abutment interface designs, (2) to compare the detorque values of the six different implant-abutment interface designs after cyclic loading, (3) to compare the detorque values of regular and wide diameter implants and (4) to compare the initial detorque values with the detorque values after cyclic loading.

## Material & Methods

Six different implant-abutment connection systems were used. The cement retained abutment and titanium screw of each system were assembled and tightened to 32 Ncm with digital torque gauge. After 10 minutes, initial detorque values were measured. The custom titanium crown were cemented temporarily and a cyclic sine curve load (20 to 320 N, 14 Hz) was applied. The detorque values were measured after cyclic loading of one million times by loading machine. One-way ANOVA test, scheffe's test and Mann-Whitney U test were used.



Fig. 1. Regular diameter implants, abutments, abutment screws and titanium crowns.

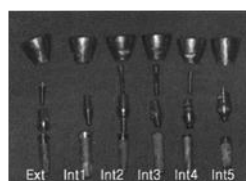

Fig. 2. Wide diameter implants, abutments, abutment screws and titanium crowns.

## Results & Conclusions

The results were as follows:

1. The initial detorque values of six different implant-abutment connections were not significantly different ( $p > .05$ ).
2. The detorque values after one million dynamic cyclic loading were significantly different ( $p < .05$ ).
3. The SSII regular and wide implant both recorded the higher detorque values than other groups after cyclic loading ( $p < .05$ ).
4. Of the wide the initial detorque values of Avana Self Tapping Implant, MIS and Tapered Screw and the detorque values of MIS implant after cyclic loading were higher than their regular counterparts ( $p < .05$ ).
5. After cyclic loading, SSII regular and wide implants showed higher de torque values than before ( $p < .05$ ).

Table 1. List of Components

Group	Brand name	Types of cemented abutments
Ext(R)	Osstem USII Implant	Hexed, collar 1mm, height 5.5mm
Ext(W)		Hexed, collar 1mm, height 5.5mm
Int1(R)	Osstem SSII Implant	non-octa, height 5.5mm
Int1(W)		non-octa, height 5.5mm
Int2(R)	Camlog®	trivam, gingival collar 1.5mm
Int2(W)		trivam, gingival collar 1.5mm
Int3(R)	Implantium®	non-hex, gingival collar 1.0mm
Int3(W)		non-hex, gingival collar 1.0mm
Int4(R)	MIS®	hexed, gingival collar 2.0mm
Int4(W)		hexed, gingival collar 2.0mm
Int5(R)	Tapered Screw Vent®	hexed, 5.5mm wide profile
Int5(W)		hexed, 5.5mm wide profile

Ext : external, Int : internal

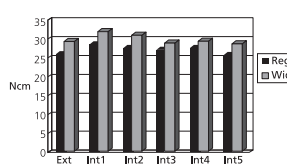


Fig. 3. Mean initial detorque value.

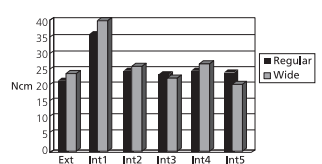


Fig. 4. Mean detorque values after cyclic loading.

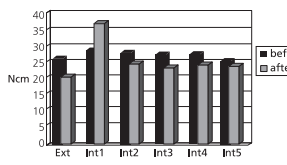


Fig. 5. Mean detorque values of regular diameter implants.

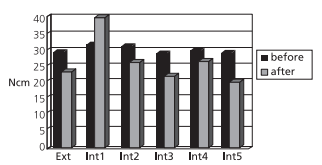


Fig. 6. Mean detorque values of wide diameter implants.

## SS SYSTEM References

### Clinical Study

1. In-Ho Cho, Jae-Hoon Lee, Young-Gyun Song, Young-Mi Kim, So-Young Jeon, Evaluation on the efficacy and safety of calcium metaphosphate coated fixture. J Adv Prosthodont 2013;5:172-8
2. Kyu-Hong Jo, Kyu-Ho Yoon, Jeong-Kwon Cheong, In-Seong Jeon. Postoperative perforation of the Schneiderian membrane in maxillary sinus augmentation: a case report. J Oral Implantol. 2012 Apr 16. [Epub ahead of print]
3. Kyu-Hong Jo, Kyu-Ho Yoon, Kwan-Soo Park, Jung-Ho Bae, Kyung-Ha You, Ji-Hoon Han, Jae-Myung Shin, Jee-Seon Baik, In-Seong Jeon, Jeong-Kwon Cheong. Thermally induced bone necrosis during implant surgery : 3 case reports. J Korean Assoc Oral Maxillofac Surg 2011;37:406-14
4. Sang-Woon Moon, Young-Kyun Kim. Analysis of Prognostic Factors after a Variety of Osstem Implant Installation. Implantology 2011;15(2):170-9
5. Jong-Chul Park, Hyun-Duck Kim, Soung-Min Kim, Myung-Jin Kim, Jong-Ho Lee. A Comparison of Implant Stability Quotients Measured Using Magnetic Resonance Frequency Analysis from Two Directions: Prospective Clinical Study during the Initial Healing Period. Clin. Oral Impl. Res. 2010;21(6):591-7
6. Young-Kyun Kim, Bum-Soo Kim, Hyo-Jung Lee, Jung-Won Hwang, Pil-Young Yun. Surgical Repositioning of an Unrestorable Implant Using a Trepine Bur: A Case Report. Int J Periodontics Restorative Dent. 2010 Mar-Apr;30(2):181-5
7. Deug-Han Kim, Eun-Kyoung Pang, Chang-Sung Kim, Seong-Ho Choi, Kyoo-Sung Cho. Non-submerged type Implant Stability Analysis during Initial Healing Period by Resonance Frequency Analysis. J Korean Acad Periodontol 2009;39(3):339-48
8. Chae-Su Lim, Min-Seok Oh, Su-Gwan Kim, Jin-Sung Park, Seo-Yoon Kim, Ka-Young Seol. Prospective Clinical Trial of Survival Rate for Two Different Implant Surfaces Using the Osstem SSII Non-submerged Implant System in Partially Edentulous Patients. J Kor Dent Sci. 2009;3(1):35-41
9. Young-Kyun Kim, Su-Gwan Kim, Hee-Kyun Oh, Yong-Geun Choi, Yong-Seok Cho, Young-Hak Oh, Jun-Sik Son. Evaluation of Peri-implant Tissue in Nonsubmerged Dental Implants: a Multicenter Retrospective Study. Oral Surg Oral Med Oral Pathol Oral Radiol Endod. 2009;108(2):189-95
10. Jong-Chul Park, Seung-Ryong Ha, Soung-Min Kim, Myung-Jin Kim, Jai-Bong Lee, and Jong-Ho Lee. A Randomized Clinical 1-year Trial Comparing Two Types of Non-submerged Dental Implant. Clin Oral Impl Res 2010;21(2):228-36
11. Young-Kyun Kim, Pil-Young Yun, Su-Gwan Kim, Bum-Soo Kim, Joo L Ong. Evaluation of Sinus Bone Resorption and Marginal Bone Loss after Sinus Bone Grafting and Implant Placement. Oral Surg Oral Med Oral Pathol Oral Radiol Endod 2009;107:e21-8
12. Hye-Ran Jeon, Myung-Rae Kim, Dong-Hyun Lee, Jung-Sub Shin, Nara-Kang. Four-year Survival Rate of RBM Surface Internal Connection Non-Submerged Implants and the Change of the Peri-Implant Crestal Bone. J Korean Assoc Maxillofac Plast Reconstr Surg 2009;31(3):237-42
13. In-Seong Jeon. Clinical Application of Osstem SSIII Implant System. J Korean Dental Success 2009;29(8):829-37
14. Seong-Yeon Lee, Young-Kyun Kim, Pil-Young Yun, Yang-jin Yi, In-Sung Yeo, Hyo-Jung Lee, Ji-Young Lee. Prospective Clinical Study of Short Implant. Scientific Poster, 4th Congress of the ICOI Korea 2009
15. Moo-Gyung Sung. User Guide of Osstem Implant Systems. Scientific Oral, The 50th Anniversary of KAP, International Prosthodontic Congress & The 6th Biennial Meeting of Asian Academy of Prosthodontics (AAP) 2009
16. Sung-Moon Back, Min-Suk Oh, Su-Kwan Kim. A Retrospective Study on the Clinical Success Rate of Osstem Implant. Key Engineering Materials 2008;361-363:1331-4
17. Su-Gwan Kim, Daniel Sun-Ho Oh. Placement of Calcium Metaphosphate-coated Dental Implants in the Posterior Maxilla: Case Reports. Hosp Dent (Tokyo)2008;20(1):39-43
18. Hong-Ju Park, Min-Suk Kook, Su-Gwan Kim, Young-Kyun Kim, Yong-Seok Cho, Gab-Lim Choi, Young-Hak Oh, Hee-Kyun Oh. Multicenter Retrospective Study of Immediate Two Different RBM Surfaced Implant Systems after Extraction. J Korean Assoc Maxillofac Plast Reconstr Surg 2008;30(3):258-65
19. Min-Suk Kook, Hong-Ju Park, Su-Gwan Kim, Young-Kyun Kim, Yong-Seok Cho, Gab-Lim Choi, Young-Hak Oh, Hee-Kyun Oh. A Retrospective Multicenter Clinical Study of Installed USII / SSII Implants after Maxillary Sinus Floor Elevation. J Kor Oral Maxillofac Surg 2008;34:341-9
20. Young-Kyun Kim, Pil-Young Yun, Jae-Hyung Im. Clinical Retrospective Study of Sinus Bone Graft and Implant Placement. J Korean Assoc Maxillofac Plast Reconstr Surg 2008;30(3):294-302
21. Young-Kyun Kim, Pil-Young Yun, Min-Jung Kwon. Short term Retrospective Clinical Study on GSII, SSIII, USIII. J Korean Implantology(KAOMI) 2008;12(2):12-22
22. Ju-Hyon Lee, Hyun-Gi Min, Jin-Sook Lee, Myung-Rae Kim, Na-Ra Kang. Resonance Frequency Analysis in Non-Submerged, Internal Type Implant with Sinus Augmentation Using Deproteinized Bovine Bone Mineral. J Korean Assoc Maxillofac Plast Reconstr Surg 2008;30(6):554-60
23. Bum-Soo Kim, Young-Kyun Kim, Pil-Young Yun, Yang-Jin Lee. Clinical Evaluation of Sinus Bone Graft Using Allograft and Xenograft. Scientific Poster, 17th Congress of EAO 2008

## SS SYSTEM References

24. Young-Kyun Kim, Hee-Kyun Oh, Su-Gwan Kim, Yong-Geun Choi, Yong-Seok Cho, Young-Hak Oh. Multicenter Retrospective Clinical Study of Osstem SSII Implant System. *J Korean Implantology(KAOMI)* 2007;11(1):20-31
25. Jong-Jin Kwon. For whom? Immediate Implant: The Factors for Successful Immediate Implant. *J Korean Clinical Implant* 2007;35(5):20-38
26. Jong-Jin Kwon, Tae-Sung Kim. Retrospective Study of Immediately Loaded Implants among Elderly Patients with Diabetes Mellitus. *Scientific Oral*, 46th Congress of the Korean Assoc Maxillofac Plast Reconstr Surg 2007
27. Min-Seok Oh, Su-Gwan Kim, Hak-Kyun Kim, Seong-Yong Moon. Prospective Clinical Study of Two Osstem SSII Implant Systems with Different Surfaces in Partially Edentulous Patients. *Scientific Oral*, 2nd Congress of the ICOI Korea 2007
28. Young-Kyun Kim, Pil-Young Yun, Dae-Il Son, Bum-Soo Kim, Jung-Won Hwang. Analysis of Clinical Application of Osstem (Korea) Implant System for 6 Years. *J Korean Implantology(KAOMI)* 2006;10(1):56-65
29. Sun-Hee Oh, Taek-Ga Kwon, Young-Kyun Kim, Jung-Won Hwang. Retrospective Study of Osstem Dental Implants; Clinical and Radiographic Results of 2.5 Years. *Scientific Poster*, 15th Congress of EAO 2006
30. Young-Kyun Kim, Jung-Won Hwang, Pil-Young Yun, Su-Gwan Kim, Chae-Heon Chung, Yong-Gun Choi, Sung-Il Song. Multicentric Prospective Clinical Study of Korean Implant System: Early Stability Measured by Periotest. *J Korean Dent Assoc* 2004;42(12):873-81

### Pre-Clinical Study

#### Biology

1. Al-Marshood MM, Junker R, Al-Rasheed A, Al Farraj, Aldosari A, Jansen JA, Anil S. Study of the Osseointegration of Dental Implants Placed with an Adapted Surgical Technique. *Clin. Oral Impl. Res.* 2011;22:753-9
2. In-Hee Cho, Hong-Young Choi, Yong-Seok Cho, Tae-Gwan Eom. Histomorphometric and Fluorescence Microscopic Evaluation of Interfacial Bone Formation around Different Dental Implants. *Scientific Poster*, 19th Congress of EAO 2010
3. Woo-Jin Jeon, Su-Gwan Kim, Sung-Chul Lim, Joo L. Ong, Daniel Sunho Oh. Histomorphometric Evaluation of Immediately Loaded SSII Implants of Different Surface Treatments in a Dog Model. *J Biomed Mater Res* 2009;90A:396-400
4. Joo-Young Lee, Su-Gwan Kim, Seong-Yong Moon, Sung-Chul Lim, Joo L. Ong, Kwang-Min Lee. A Short-term Study on Immediate Functional Loading and Immediate Nonfunctional Loading Implant in Dogs: Histomorphometric Evaluation of Bone Reaction. *Oral Surg Oral Med Oral Pathol Oral Radiol Endod* 2009;107:519-24
5. Se-Hoon Kim, Byung-Ho Choi, Jingxu Li, Han-Sung Kim, Chang-Yong Ko, Seung-Mi Jeong, Feng Xuan, Seoung-Ho Lee. Peri-implant Bone Reactions at Delayed and Immediately Loaded Implants: An Experimental Study. *Oral Surg Oral Med Oral Pathol Oral Radiol Endod* 2008;105:144-8
6. Sung-Han Sul, Byung-Ho Choi, Jingxu Li, Seung-Mi Jeong, Feng Xuan. Histologic Changes in the Maxillary Sinus Membrane after Sinus Membrane Elevation and the Simultaneous Insertion of Dental Implants without the Use of Grafting Materials. *Oral Surg Oral Med Oral Pathol Oral Radiol Endod* 2008;105:e1-5
7. Sung-Han Sul, Byung-Ho Choi, Jingxu Li, Seung-Mi Jeong, Feng Xuan. Effects of Sinus Membrane Elevation on Bone Formation around Implants Placed in the Maxillary Sinus Cavity: An Experimental Study. *Oral Surg Oral Med Oral Pathol Oral Radiol Endod* 2008;105:684-7
8. Byung-Ho Choi, Jingxu Li, Han-Sung Kim, Chang-Yong Ko, Seung-Mi Jeong, Feng Xuan. Comparison of Submerged and Nonsubmerged Implants Placed without Flap Reflection in the Canine Mandible. *Oral Surg Oral Med Oral Pathol Oral Radiol Endod* 2008;105:561-5
9. Seung-Mi Jeong, Byung-Ho Choi, Jingxu Li, Han-Sung Kim, Chang-Yong Ko, Seoung-Ho Lee. Influence of Abutment Connections and Plaque Control on the Initial Healing of Prematurely Exposed Implants: An Experimental Study in Dogs. *J Periodontol* 2008;79(6):1070-4
10. Soo-Young Bae, Su-Kyoung Kim, Eun-Jung Kang, Young-Bae An, Gyu-Sub Eom, Tae-Gwan Eom. The Effect of Hydroxyapatite-blasted Titanium Surface Roughness on Osteoblast-like Cell Line MG-63. *Scientific Poster*, Meeting of the Korean Society for Biomaterials 2008
11. Seung-Mi Jeong, Byung-Ho Choi, Jingxu Li, Han-Sung Kim, Chang-Yong Ko, Jae-Hyung Jung, Hyeon-Jung Lee, Seoung-Ho Lee, Wilfried Engelke. Flapless Implant Surgery: An Experimental Study. *Oral Surg Oral Med Oral Pathol Oral Radiol Endod* 2007;104:24-8
12. Seoung-Ho Lee, Byung-Ho Choi, Jingxu Li, Seung-Mi Jeong, Han-Sung Kim, Chang-Yong Ko. Comparison of Corticocancellous Block and Particulate Bone Grafts in Maxillary Sinus Floor Augmentation for Bone Healing around Dental Implants. *Oral Surg Oral Med Oral Pathol Oral Radiol Endod* 2007;104(3):324-8
13. Jae-Wan Park, Min-Suk Kook, Hong-Ju Park, Uttom Kumar Shet, Choong-Ho Choi, Suk-Jin Hong, Hee-Kyun Oh. Comparative Study of Removal Effect on Artificial Plaque from RBM Treated Implant. *J Korean Assoc Maxillofac Plast Reconstr Surg* 2007;29(4):309-20
14. Ki-Jong Sun, Jae-Young Park, Eun-Gyeong Jung, Mee-Ran Shin, Yun-Sang Kim, Sung-Hee Pi, Hyung-Shik Shin, Hyung-Keun You. Comparative Study of Osseointegration on Different Immediate Implants in Extraction Sockets of Beagle Dogs. *J Korean Acad Periodontol* 2007;37(2):209-21
15. Young-Jong Kim, Su-Gwan Kim, Young-Kyun Kim, Suk-Young Kim. Analysis of Failed Implants. *J Korean Implantology (KAOMI)* 2007;11(3):46-58

### Pre-Clinical Study

#### Biomechanics

1. Ki-Seong Kim, Young-Jun Lim, Myung-Joo Kim, Ho-Beom Kwon, Jae-Ho Yang, Jai-Bong Lee, Soon-Ho Yim. Variation in the Total Lengths of Abutment/Implant Assemblies Generated with a Function of Applied Tightening Torque in External and Internal Implant-Abutment Connection. *Clin. Oral Impl. Res.* 2011;22:834-9
2. Il-Song Park, Sang-Yong Won, Tae-Sung Bae, Kwang-Yeob Song, Charn-Woon Park, Tae-Gwan Eom, Chang-Mo Jeong. Fatigue Characteristics of Five Types of Implant-Abutment Joint Designs. *Met. Mater. Int.* 2008;14(2):133-8
3. Hyon-Mo Shin, Chang-Mo Jeong, Young-Chan Jeon, Mi-Jeong Yun, Ji-Hoon Yoon. Influence of Tightening Torque on Implant-Abutment Screw Joint Stability. *J Kor Acad Prosthodont* 2008;46(4):396-408
4. Chun-Yeo Ha, Chang-Whe Kim, Young-Jun Lim, Myung-Joo Kim. Effect of Casting Procedure on Screw Loosening of UCLA Abutment in Two Implant-Abutment Connection Systems. *J Kor Acad Prosthodont* 2008;46(3):246-54
5. Ho-Yeon Won, In-Ho Cho, Joon-Seok Lee. A Study of SmartpegTM's Lifetime according to Sterilization for Implant Stability. *J Kor Acad Prosthodont* 2008;46(1):42-52
6. Jae-Kyoung Park, Chang-Mo Jeong, Young-Chan Jeon, Ji-Hoon Yoon. Influence of Tungsten Carbide/Carbon Coating of Implant-Abutment Screw on Screw Loosening. *J Kor Acad Prosthodont* 2008;46(2):137-47
7. Chun-Yeo Ha, Chang-Whe Kim, Young-Jun Lim, Myung-Joo Kim, Ho-Bum Kwon. The Influence of Abutment Angulation on Screw Loosening of Implant in the Anterior Maxilla. *Scientific Poster*, J Kor Acad Prosthodont 2008 Conference
8. Si-Yeob Kim, Byung-kook Kim, Jin-Ho Heo, Ju-Youn Lee, Chang-Mo Jeong, Yong-Deok Kim. Evaluation of Stability of Double Threaded Implant-Emphasis on Initial Stability Using Osstell MentorTM; Part I. *J Kor Acad Stomatog Func Occlusion* 2007;23(4):327-36
9. Jung-Bo Huh, Sok-Min Ko. The Comparative Study of Thermal Inductive Effect Between Internal Connection and External Connection Implant in Abutment Preparation. *J Kor Acad Prosthodont* 2007;45(1):60-70
10. Gap-Yong Oh, Sung-Hwa Park, Seok-Gyu Kim. Influence of Implant Fixture Design on Implant Primary Stability. *J Kor Acad Prosthodont* 2006;45(1):98-106
11. Chae-Heon Chung. Detorque Force of TiN-coating Abutment Screw with Various Coating Thickness After Repeated Closing and Opening. *Scientific Oral*, 12th International College of Prosthodontists Meeting
12. Jin-Uk Choi, Chang-Mo Jeong, Young-Chan Jeon, Jang-Seop Lim, Hee-Chan Jeong, Tae-Gwan Eom. Influence of Tungsten Carbide/Carbon on the Preload of Implant Abutment Screws. *J Kor Acad Prosthodont* 2006;44(2):229-42
13. Yong-Suk Cho, Chul-Hyun Jeong, Tae-Soo Kim, Dong-Hoon Jang, Tae-Gwan Eom. Temperature Measurement During Implant-Site Preparation. *Scientific Poster*, 15th Congress of EAO 2006
14. Ji-Hoon Yoon, Sung-Geun Lee, Chang-Mo Jeong, Tae-Gwan Eom. The Study of Dynamic Behaviour about Implant System with WC/C Coating. *Scientific Poster*, 15th Congress of EAO 2006
15. Byung-Kook Kim, Tae-Gwan Eom, Kyu-Ok Choi, Lee GH. Correlation Between Insertion Torque and Primary Stability of Dental Implant by Block Bone Test. *Scientific Poster*, 15th Congress of EAO 2006
16. Chun-Yeo Ha, Chang-Whe Kim, Young-Jun Lim, Kyung-Soo Jang. The Effect of Internal Implant-Abutment Connection and Diameter on Screw Loosening. *J Kor Acad Prosthodont* 2005;43(3):379-92
17. Kwang-Hoon Kim, Chang-Mo Jeong, Ji-Hoon Yoon, Ji-Yun Seong. Effect of Implant-Abutment Joint Design on Dynamic Fatigue Strength. *Scientific Poster*, 20th Congress of AO 2005
18. Tae-Gwan Eom, Chang-Mo Jeong, Kwang-Hoon Kim. The Effect of Tightening Torque on Reliability of Joint Stability. *Scientific Poster*, 14th Congress of EAO 2005
19. Ji-Hoon Yoon, Chang-Mo Jeong, Tae-Gwan Eom, Mi-Hyun Cheon. Effect Joint Design on Static and Dynamic Strength. *Scientific Poster*, 14th Congress of EAO 2005
20. Tae-Hee Byun, Kwang-Hoon Kim. Study on the Adaptation to the Investment Water-Powder Ratio by Abutment and Casting Crown. *Scientific Poster*, Kor Dent Technician Associate 2005 Conference
21. Byung-Gi Cho, Jae-Ho Ryu. Study of Possibility Direct Casting on Titanium Abutment. *Scientific Poster*, Kor Dent Technician Associate 2005 Conference
22. Byung-Soo Bae, Jae-Ho Ryu. Investigation of the Resin Adhesion and Task Convenience for Surface Shape. *Scientific Poster*, Kor Dent Technician Associate 2005 Conference

## Success Rate and Marginal Bone Loss of Osstem USII Plus Implants: Short Term Clinical Study

Sun-Keun Kim, Jee-Hwan Kim, Keun-Woo Lee, Kyoo-Sung Cho, Dong-Hoo Han  
J Korean Acad Prosthodont 2011;49(3):206-13

### Objective

The aim of this study was to evaluate the clinical value of Osstem USII Plus system implants. Clinical and radiographic data were analyzed for 88 implants placed and functionally loaded for a 12 month period at the Yonsei University Dental Hospital.

### Materials & Methods

Based on the patient's medical records, clinical factors and their effects on implant marginal bone resorption, distribution and survival rate were analyzed. The marginal bone loss was evaluated at implant placement and during a 6 to 12 months functional loading period. The independent sample t-test was used to evaluate the interrelationship between the factors ( $\alpha = 0.05$ ), and one way repeated measures ANOVA was used to compare the amount of marginal bone resorption.

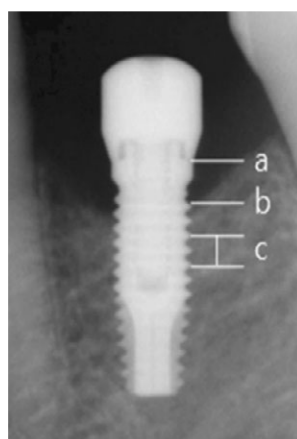


Fig. 1. References used to measure actual marginal bone loss.  
a: top level of implant platform  
b: implant to marginal bone contact level  
c: interthread distance of three threads

Table 1. Marginal bone loss around implants according to observation period

	Marginal bone resorption (mm) (Mean $\pm$ SD)			t-test P value
	Mesial	Distal	Total	
Sur-B	0.25 $\pm$ 0.48	0.24 $\pm$ 0.41	0.24 $\pm$ 0.40	.697
B-12 month	0.20 $\pm$ 0.50	0.18 $\pm$ 0.38	0.19 $\pm$ 0.43	.756
Sur-12 month	0.44 $\pm$ 0.67	0.42 $\pm$ 0.53	0.43 $\pm$ 0.56	.439

Sur-B: period from surgery to baseline (functional loading)

B-12 month: period from baseline to 12 month

Sur-12 month: period from surgery to 12 month post baseline, SD: standard deviation

### Results

The cumulative survival rate for 88 implants was 100%. The marginal bone resorption from implant placement to prosthetic delivery was 0.24 mm and the average marginal bone resorption from prosthetic delivery to 12 months of functional loading was 0.19 mm. The total average bone resorption from implant placement to 12 months of functional loading was 0.43 mm. There were no statistically differences in the amount of marginal bone resorption when implants were placed in the maxilla or the mandible ( $p > .05$ ), however, implants placed in the posterior areas showed significantly more marginal bone loss than those placed in the anterior areas ( $p < .05$ ).

### Conclusions

Based on these results, the short term clinical success rate of RBM surface treated external connection domestic implants showed satisfactory results and the marginal bone loss was in accord with the success criteria of dental implants.

Table 2. Distribution of implants by bone resorption

Amount of bone resorption (mm)	Number of implants
<0.2	40
0.3	10
0.4	3
0.5	9
0.6	5
0.7	3
0.8	2
0.9	1
1	2
1.2	7
1.5	4
2	1
3	1

## The Study of Bone Density Assessment on Dental Implant Sites

Su-Won Park, Soo-Mi Jang, Byoung-Hwan Choi, Han-Na Son, Bong-chan Park, Chang-Hwan Kim, Jang-Ho Son, Lel-Yong Sung, Ji-Ho Lee, Yeong-Cheol Cho  
J Korean Assoc Oral Maxillofac Surg 2010;36(5):417-22

### Objective

Bone density is one of the important factors for the long term success of endosseous implants. The bone density varies from site to site and from patient to patient. A preoperative evaluation of the bone density is quite useful to oral surgeons for planning dental implantation. More accurate information on the bone density will help surgeons identify suitable implant sites, thereby increase the success rate of dental implantation.

This study examined the correlation between the bone density measured preoperatively by computed tomography (CT) and the implant primary stability measured by resonance frequency analysis. Furthermore, the effects of the implant sites, gender, age and generalized systemic disorder patients on the bone density and primary implant stability were examined.

### Materials & Methods

One hundred and fourteen patients were selected. None of the patients had undergone a tooth extraction or bone graft history in the previous year. Preoperatively, the patients underwent CT scanning to evaluate the Hounsfield unit (HU), and resonance frequency analysis (RFA) was used to evaluate the implant primary stability at the time of implant installation. All implants were 4.0 mm diameter and 11.5 mm length USII. All patients were recorded and the HU and implant stability quotient (ISQ) value were evaluated according to the sites, gender and age.

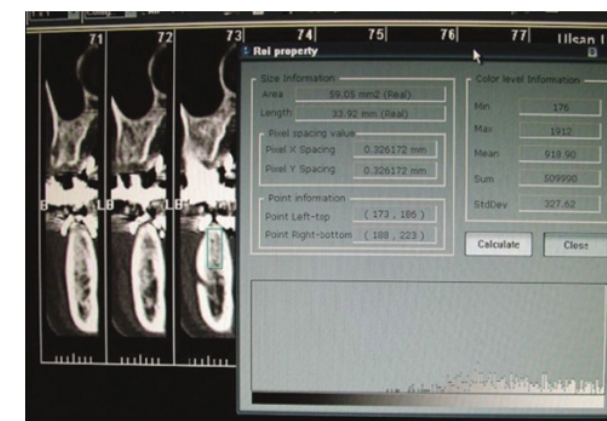


Fig. 1. Image of transaxial cut of Somatom computed tomography (CT). The hounsfield unit (HU) measurement feature of CT was utilized to evaluate the bone density.

### Results

The highest HU values were found in the mandibular anterior site (827.6 $\pm$ 151.4), followed by the mandibular molar site (797 $\pm$ 135.1), mandibular premolar site (753.8 $\pm$ 171.2), maxillary anterior site (726.3 $\pm$ 154.4), maxillary premolar site (656.7 $\pm$ 173.8) and maxillary molar site (621.5 $\pm$ 164.9). The ISQ value was the highest in the mandibular premolar site (81.5 $\pm$ 2.4) followed by the mandibular molar site (80.0 $\pm$ 5.7), maxillary anterior site (77.4 $\pm$ 4.1), mandibular anterior site (76.4 $\pm$ 11.9), maxillary premolar site (74.2 $\pm$ 14.3) and maxillary molar site (73.7 $\pm$ 7.4).

The mean HU and ISQ value were similar in females and males. (HU:  $p = 0.331$ , ISQ:  $p = 0.595$ ) No significant difference was also found in the age group respectively. However, the correlation coefficients between the variables showed a closed correlation between the HU and ISQ value.

### Conclusions

Based on these results, the short term clinical These results showed close correlation between the bone density (HU) and primary stability value (ISQ) at the time of implant installation (Correlation coefficients=0.497,  $p < 0.01$ ).

These results strengthen the hypothesis that it might be possible to predict and quantify the initial implant stability and bone density from a presurgical CT diagnosis.

Table 1. Results of ANOVA for Hounsfield unit (HU) and implant

	No	HU	ISQ
Zone 1	14	723.6 $\pm$ 154.4	74.4 $\pm$ 4.1
Zone 2	14	656.7 $\pm$ 173.8	74.2 $\pm$ 14.3
Zone 3	23	621.5 $\pm$ 164.9	73.7 $\pm$ 7.4
Zone 4	8	827.6 $\pm$ 151.4	76.4 $\pm$ 11.9
Zone 5	12	753.8 $\pm$ 171.2	81.5 $\pm$ 2.4
Zone 6	43	797.7 $\pm$ 135.1	80.0 $\pm$ 5.7
p value*		0	0.011

(No: number of patients, Zone 1: maxillary anterior, Zone 2: maxillary premolar, Zone 3: maxillary molar, Zone 4: mandibular anterior, Zone 5: mandibular premolar, Zone 6: mandibular molar, \*: p value was taken by ANOVA)

Table 2. Partial correlation coefficients between the variables

	No	HU
ISQ	(-)	0.497*
HU	0.497*	(-)
Age	-0.104	-0.125

(HU: Hounsfield unit, ISQ: implant stability quotient, \*:  $p < 0.01$ , adjusted by sex and systemic diseases)

## A Retrospective Evaluation of Implant Installation with Maxillary Sinus Augmentation by Lateral Window Technique

Se-Il Ki, Min-Gi Yu, Young-Joon Kim, Min-Suk Kook, Hong-Ju Park, Uttom Kumar Shet, Hee-Kyun Oh  
J Korean Assoc Maxillofac Plast Reconstr Surg 2008;30(5):457-64

### Objective

The aim of this study was to evaluate the clinical results of implants which were installed with maxillary sinus elevation by using lateral window technique.

### Materials & Methods

We performed the maxillary sinus elevation by lateral window technique to 87 patients who visited Dept. of Oral & Maxillofacial Surgery, Chonnam National University Hospital from January, 2003 to January, 2007. When the residual bone height was from 3 mm to 7 mm, the sinus elevation and simultaneous implant installation was mostly performed. When the residual bone height was less than 3 mm, the sinus elevation was performed and the delayed implant installation was done after 5 or 6 months. No artificial membranes were used for coverage of the lateral bony window site and freeze dried fibrin sealant was applied to the grafted bone. The mean follow-up period was 28.5 months (ranged from 10 months to 48 months).

Table 1. Survival rates of simultaneously installed implants

Residual bone height (mm)	No. of implant	No. of failed implant	Survival rate (%)
> 7	106	2	98.1
7 - 3	132	0	100
< 3	11	0	100
Total	249	2	99.2

Table 2. Survival rates of delayed installed implants

Residual bone height (mm)	No. of implant	No. of failed implant	Survival rate (%)
> 7	9	0	100
7 - 3	48	0	100
< 3	84	0	100
Total	141	0	100

### Results

1. Unilateral sinus elevations were performed in 51 patients and bilateral sinus elevations were performed in 36 patients. And the total number of sinus elevation procedure was 123 cases.
2. The sinus elevation and simultaneous implant installation was performed in 89 sinuses and 249 implants were installed. The sinus elevation and delayed implant installation was performed in 44 sinuses and 141 implants were installed. The total number of implants were 390 in 133 sinuses. The average healing period after sinus elevations was 6.1 months in delayed implant installation.
3. Only autogenous bone, autogenous bone mixing with allografts or autogenous bone mixing with xenografts were used as graft materials.
4. The average period from first surgery to second surgery was about 7.2 months.
5. Some patients complications, such as perforation of sinus membrane, swelling, infection and exposure of cover screw. Two implants were removed in the infected sinus.
6. The survival rate of implants with maxillary sinus elevation by lateral window technique was 99.5% and the success rate of implants was 95.1%.

### Conclusions

These results indicated that the implants which were installed with maxillary sinus elevation by lateral window technique showed high survival and success rates.

## Multicenter Retrospective Clinical Study of Osstem USII Implant System in Type IV Bone

Su-Gwan Kim, Chul-Min Park, Young-Kyun Kim, Hee-Kyun Oh, Gab-Lim Choi, Young-Hak Oh  
J Korean Implantology(KAOMI) 2007;11(3):22-9

The purpose of this study is to evaluate the success rate of the Osstem USII (Seoul, Korea) placed in the edentulous area of type 4 bone quality.

178 USII implants that had been inserted between 1997 and 2005 were followed up for mean 29.4 months. With medical records and radiographs we analysis the distribution of patients' age and gender, position of implant, the kind of surgical technique, the type of prostheses, amount of bone resorption survival rate and success rate of implants. From these analysis we got the following results.

In the distribution of implants by site, 167 implants were placed on maxilla and only 11 implants on mandibule. And the resorption of crestal bone more than 1mm was measured at only 5 implants. The mean plaque, gingival inflammatory and calculus index were measured 0.56, 0.31, 0.01. The survival rate was 100% and success rate was 98.8% during 29.4 months of mean following up period.

As a result, we got the excellent clinical results of USII implant system at bone quality of type 4.

Table 1. Distribution of operation methods

Operation method	No. of implants
Conventional method	54
SL via lateral window	114
SL via osteotome technique	9
GBR	1

Table 2. Distribution of implants by type of prostheses

Prostheses	No. of implants
Single	3
Fixed partial	136
Fixed complete	33
Others	6

Table 3. Distribution of implants by bone resorption

Amount of bone resorption (mm)	No. of implants
None	165
0-0.9	2
1.0-2.0	5
>2.0	0

## Multicenter Retrospective Clinical Study of Osstem USII Implant System in Complete Edentulous Patients

Su-Gwan Kim, Min-Suk Oh, Young-Kyun Kim, Hee-Kyun Oh, Gab-Lim Choi, Young-Hak Oh  
J Korean Implantology(KAOMI) 2007;11(3):12-21

In this study, we analyzed data for edentulous patients from multiple centers after installation of the Osstem USII system in a retrospective study of patient gender, age, implant area, additional surgery, type of prosthesis, and the implant survival and success rates. We then analyzed the success rate after prosthetic restoration using implants in completely edentulous patients to validate the usefulness of the USII system.

Between 1997 and 2005, of the patients who visited regional dental clinics and private clinics nationwide (Department of Oral and Maxillofacial Surgery, Chosun University Dental College; Department of Oral and Maxillofacial Surgery and dental clinics, Seoul National University Bundang Hospital; Department of Oral and Maxillofacial Surgery, Chonnam University Dental School; dental clinics, Daedong Hospital; All Dental Private Office) and underwent the Osstem USII system implant procedure, our multicenter retrospective study examined 44 completely edentulous patients (mean age 63.3 years) who received 276 implants. The following results were obtained.

1. Eight of the 44 patients had systemic diseases, including 3 patients with diabetes, 2 patients with cardiovascular disease, and 1 patient each with cerebral infarction, hypertension, bronchial asthma, and Parkinson's disease.
2. The oral hygiene of the 44 patients was classified as good in 36 patients, somewhat poor in 7 patients, moderately poor in 1 patient, and very poor in 0 patients.
3. Of the implants installed, 80 were 20 mm long, 65 were 11.5 mm long, 64 were 13 mm long, and 37 were 15mm long; 175, 52, and 23 implants had diameters of 4.0, 3.75, and 3.3 mm, respectively.
4. When opposing teeth were encountered, 60 were natural teeth, 13 were porcelain, 40 had gold crowns, 7 were resin teeth, 90 were total dentures, and 66 were implant-repaired opposing teeth.
5. After implant installation, no bone resorption of the alveolar crest occurred in 181 cases, and more than 1 mm of bone loss took place in 44 cases.

6. The mean calculus index for the soft tissues near the implants in 215 cases was 0.11, and the gum inflammation index assessed in 226 cases averaged 0.34. The plaque index measured in 225 cases averaged 0.55, and the width of the attached gingiva measured in 222 cases averaged 2.05 mm.
7. For implant surgery, no additional surgery was performed in 161 cases (58.3%); maxillary sinus elevation via a lateral window was performed in 45 cases (16.3%); guided bone regeneration (GBR) was performed in 42 cases (15.2%); simultaneous maxillary sinus elevation and GBR were performed in 6 cases (2.1%); and veneer grafting was performed in 10 cases (3.6%).
8. According to the implant method, two implants installed with sinus lifting via a lateral window failed, for a survival rate of 95.55% (43/45). Temporary complications developed with the other procedures, but were resolved in all cases, giving good results.
9. Of the 276 implants installed, two failed and were removed for a final survival rate of 99.27%.

Table 1. Distribution of implants by bone resorption

Amount of bone resorption (mm)	No. of implants
None	181
0-0.9	6
1.0-2.0	35
>2.0	9

Table 2. Survival rate on total implant

Implant status	No. of implants
Survival count	274
Fail count	2
Total	276
Survival (percentage)	99.27%

## Retrospective Multicenter Cohort Study of the Clinical Performance of 2-Stage Implants in South Korean Populations

Seok-Min Ko, Jeong-Keun Lee, Steven E. Eckert, Yong-Geun Choi  
Int J Oral & Maxillofac Implants 2006;21(5):785-8

### Objective

To evaluate long-term follow-up clinical performance of dental implants in use in South Korean populations.

### Materials & Methods

A retrospective multicenter cohort study design was used to collect long-term follow-up clinical data from dental records of 224 patients treated with 767 2-stage endosseous implants at Ajou University Medical Center and Bundang Jesaeng Hospital in South Korea from June 1996 through December 2003. Exposure variables such as gender, systemic disease, location, implant length, implant diameter, prosthesis type, opposing occlusion type, and date of implant placement were collected. Outcome variables such as date of implant failure were measured.

### Results

Patient ages ranged from 17 to 71.7 years old (mean age, 45.6 years old). Implants were more frequently placed in men than in women (61% versus 39%, or 471 men versus 296 women). Systemic disease was described by 9% of the patients. All implants had hydroxyapatite-blasted surfaces. Most of the implants were 3.75 mm in diameter. Implant lengths 10 mm, 11.5 mm, 13 mm, and 15 mm were used most often. Differences of implant survival among different implant locations were observed. Implants were used to support fixed partial dentures for the majority of the restorations. The opposing dentition was natural teeth for about 50% of the implants. A survival rate of 97.9% (751 of 767) was observed after 4.5 years (mean, 1.95 ± 1.2 years).

### Conclusions

Clinical performance of 2-stage dental implants demonstrated a high level of predictability. The results achieved with a South Korean population did not differ from results achieved with diverse ethnic groups (Cohort Study).

Table 1. Implant Failure and Survival by Year

Year	Implants at start of interval	Implants lost to follow-up	Failure	% of total failure	Cumulative failure
1	767	754	13	81.3	98.3
2	754	752	2	12.5	98.0
3	752	751	1	6.2	97.9
4	751	751	0	0	97.9
4.5	751	751	0	0	97.9



# The Effects of Surface Roughness on the Sandblasted with Large Grit Alumina and Acid Etched Surface Treatment: In Vivo Evaluation

Hong-Young Choi, Jae-June Park, In-Hee Cho, Tae-Kwan Eom  
Scientific Poster, 20th Congress of EAO 2011

## Objective

The aim of the present study was to evaluate the effect of roughness on the sandblasted with large grit alumina and acid etched surface, which were involved with the in - vivo removal torque test.

## Materials & Methods

Three kinds of implants with different surface topographies were made by properly changing the blasting and acid-etching processes. This involved changing things like the blasting material, media size, blowing pressure, and acid-etching time. In ten micro-pigs, three submerged implants were placed in the tibia. Groups were divided into three groups: RBM (Ra 1.5 $\mu$ m), Small SA (Ra 1.5 $\mu$ m) and SA (Ra 2.8 $\mu$ m). The micro-pigs were sacrificed following a 2 and 4 week healing period. After 2 and 4 weeks of healing, the micro-pigs were sacrificed and all implants were evaluated by removal torque testing.

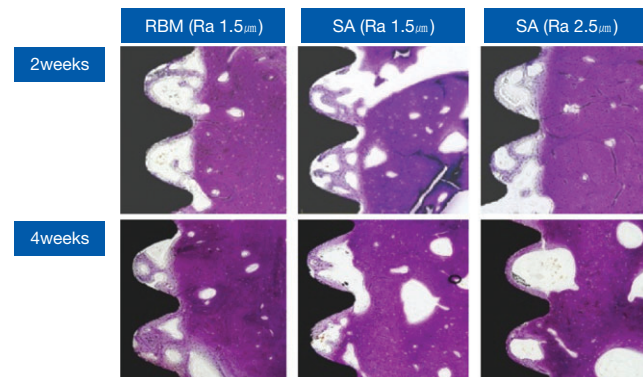


Fig. 1. The ground sections illustrate the result of healing (original magnification, x 100).

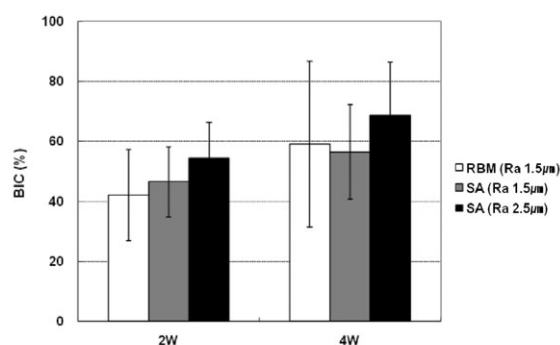


Fig. 2. BIC analysis.

## Results

There were no statistically significant differences between the groups. The RBM surface and SA with small roughness (Ra 1.5 $\mu$ m) had relatively similar removal torque values at both 2 weeks and 4 weeks, but the SA surface with higher roughness (Ra 2.8 $\mu$ m) showed a higher removal torque value than small Ra SA in 4 weeks ( $p < .05$ ).

## Conclusion

The contribution of macro and micro topography to the anchorage of SA implants was determined. For the SA surface treatment, the macro-topography with high surface roughness is more effective in a removal torque test than micro topography in the acid etching process. The SA implant presented a higher removal torque than the RBM surface.

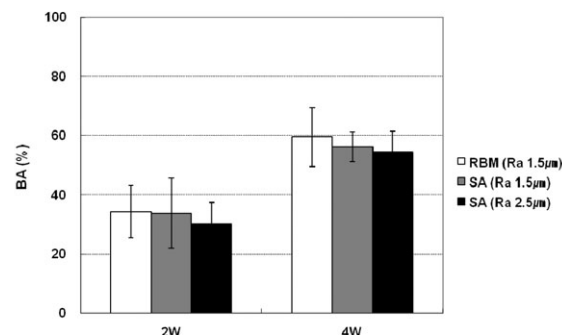


Fig. 3. BA analysis.

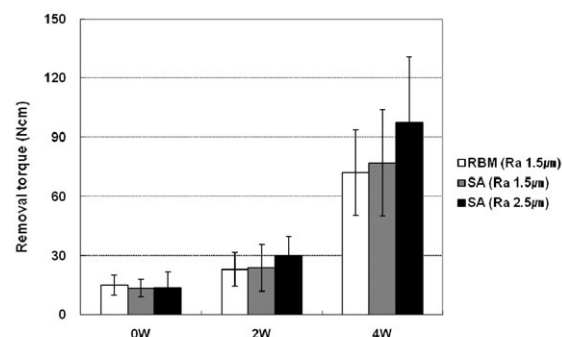


Fig. 4. Removal torque measurements.

# Effects of Different Depths of Gap on Healing of Surgically Created Coronal Defects Around Implants in Dogs: A Pilot Study

Hong-Cheol Yoon, Jung-Yoo Choi, Ui-Won Jung, Eun-Kyung Bae, Seong-Ho Choi, Kyoo-Sung Cho, Ho-Yong Lee, Chong-Kwan Kim, June-Sung Shim  
J Periodontol 2008;79: 355-61

## Objective

This study investigated the bone growth pattern in surgically created coronal defects with various depths around implants in dogs.

## Materials & Methods

Four mongrel dogs were used. All mandibular premolars were extracted under general anesthesia and left to heal for 2 months. After osteotomy, bony defects were prepared in test sites, using a stepped drill with a diameter of 6.3 mm and two depths: 2.5 mm (test sites 1 [T1]) and 5.0 mm (test sites 2 [T2]). In the control sites, the implants were placed after osteotomy without any coronal defects. T1, T2, and control sites were prepared in the right and left sides of the mandible. Six implants, 3.3 mm in diameter and 10 mm in length, were placed in each dog; the implants were submerged completely.

Two dogs were sacrificed 8 weeks after surgery, and the other two dogs were sacrificed 12 weeks after surgery. The stability of all implants was measured with a resonance frequency analyzer after placement and after sacrifice. All sites were block-dissected for ground sectioning and histologic examination.

## Results

After 12 weeks of healing, only T2 were not filled fully with bone. At week 8, the mean bone-to-implant contact (BIC) was 47.7% for control, 43.6% for T1, and 22.2% for T2. At week 12, the control BIC was 56.7% and the 2.5 mm defect had a greater BIC (58.8%). However, in the 0.5 mm defect, the BIC was 35.1%. At insertion, stability was reduced at sites with a greater defect depth. Similar stability was noted in all specimens after 8 and 12 weeks of healing.

## Conclusions

Bone healing between an implant and marginal bone was compromised at sites with a deeper defect when the width of the bone defect was 1.5 mm.

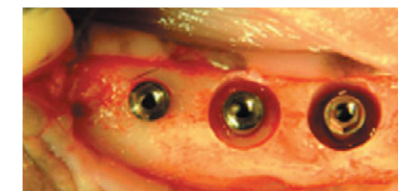

Fig. 1. Clinical photograph of control, T1, and T2.

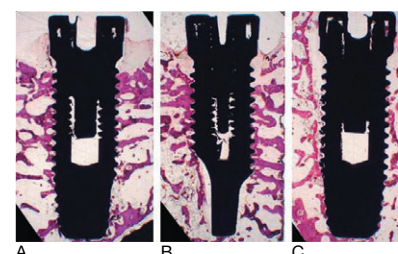


Fig. 2. Longitudinal sections after 8 weeks of healing in control (A), T1 (B), and T2 (C) (original magnification  $\times 10$ ).

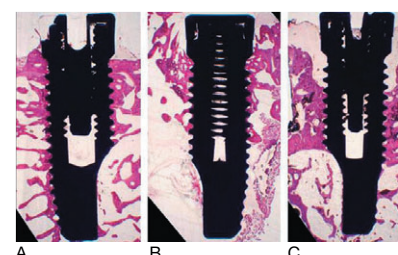


Fig. 3. Longitudinal sections after 12 weeks of healing in control (A), T1 (B), and T2 (C) (original magnification  $\times 10$ ).

Table 1. BIC (%; mean  $\pm$  SD) in the coronal 5 mm of the implant

	Control	T1 (2.5 mm)	T2 (5.0 mm)
8 weeks	47.7 $\pm$ 14.7	43.6 $\pm$ 19.0	22.2 $\pm$ 14.7
12 weeks	56.7 $\pm$ 17.0	58.8 $\pm$ 12.0	35.1 $\pm$ 8.0

Table 2. Distance (mm; mean  $\pm$  SD) from the implant margin to the most coronal level of contact between bone and implant

	Control	T1 (2.5 mm)	T2 (5.0 mm)
8 weeks	0.75 $\pm$ 0.26	1.20 $\pm$ 0.59	1.98 $\pm$ 1.45
12 weeks	0.59 $\pm$ 0.36	0.36 $\pm$ 0.40	2.52 $\pm$ 1.06

Table 3. Implant stability quotient values (mean  $\pm$  SD)

	Control	T1 (2.5 mm)	T2 (5.0 mm)
Insertion	72.8 $\pm$ 5.2	65.0 $\pm$ 9.2	55.3 $\pm$ 9.0
8 weeks	79.7 $\pm$ 9.2	79.3 $\pm$ 2.5	78.1 $\pm$ 9.6
12 weeks	74.8 $\pm$ 9.0	78.0 $\pm$ 6.3	72.0 $\pm$ 6.6

## The Effect of Surface Treatment of the Cervical Area of Implant on Bone Regeneration in Mini-Pig

Jin-Yong Cho, Young-Jun Kim, Min-Gi Yu, Min-Suk Kook, Hee-Kyun Oh, Hong-Ju Park  
J Korean Assoc Oral Maxillofac Surg 2008;34:285-92

### Objective

The present study was performed to evaluate the effect of surface treatment of the cervical area of implant on bone regeneration in fresh extraction socket following implant installation.

### Materials & Methods

The four minipigs, 18 months old and 30 kg weighted, were used. Four premolars of the left side of both the mandible and maxilla were extracted.  $\varnothing$  3.3 mm and 11.5 mm long USII Plus implants (Osstem Implant, Korea) with resorbable blasting media (RBM) treated surface and USII implants (Osstem Implant, Korea) with machined surface at the top and RBM surface at lower portion were installed in the socket. Stability of the implant was measured with Osstell™ (Model 6 Resonance Frequency Analyser: Integration Diagnostics Ltd., Sweden). After 2 months of healing, the procedures and measurement of implant stability were repeated in the right side by same method of left side. At four months after first experiment, the animals were sacrificed after measurement of stability of all implants, and biopsies were obtained.

### Results

Well healed soft tissue and no mobility of the implants were observed in both groups. Histologically satisfactory osseointegration of implants was observed with RBM surface, and no foreign body reaction as well as inflammatory infiltration around implant were found. Furthermore, substantial bone formation and high degree of osseointegration were exhibited at the marginal defects around the cervical area of USII Plus implants. However, healing of USII implants was characterized by the incomplete bone substitution and the presence of the connective tissue zone between the implant and newly formed bone. The distance between the implant platform (P) and the most coronal level of bone-to-implant contact (B) after 2 months of healing was  $2.66 \pm 0.11$  mm at USII implants group and  $1.80 \pm 0.13$  mm at USII Plus implant group. The P-B distance after 4 months of healing was  $2.29 \pm 0.13$  mm at USII implants group and  $1.25 \pm 0.10$  mm at USII plus implants group. The difference between both groups regarding the length of P-B distance was statistically significant ( $p < .05$ ). Concerning the resonance frequency analysis (RFA) value, the stability of USII Plus implants group showed relatively higher RFA value than USII implants group.

### Conclusions

The current results suggest that implants with rough surface at the cervical area have an advantage in process of bone regeneration on defect around implant placed in a fresh extraction socket.

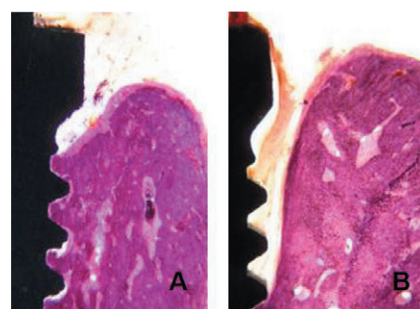


Fig. 1. The ground sections illustrate the result of healing.  
A, The defect adjacent to coronal portion of USII Plus implants is filled with newly formed bone.  
B, The defect adjacent to coronal portion of USII implants is separated from the implant surface by a connective tissue.

## Comparison of Push-in Versus Pull-out Tests on Bone-Implant Interfaces of Rabbit Tibia Dental Implant Healing Model

Wook-Jin Seong, Shahrzad Grami, Soo-Cheol Jeong, Heather J. Conrad, James S. Hodges  
Clin Implant Dent Res 2013;15(3):460-9

### Objective

This study aimed to investigate whether push-in and pull-out tests measure mechanical properties of the bone-implant interface differently, and which test is more sensitive to changes over the healing period.

### Materials & Methods

Two identical self-threading dental implants ( $\varnothing$  3.3 x 8.5 mm) were placed in medial surface of the proximal condyles of left and right tibias of 20 rabbits (40 implants total). Five rabbits each were sacrificed after 1, 4, 8, and 12 weeks of healing. Push-in test was performed on one side's tibia implant and pull-out on the other side's implant, at a rate of 6 mm/min. Primary and secondary implant stabilities and tibia weight were measured on all implants.

### Results

The push-in test generated significantly higher failure load ( $p = .0001$ ; 530 N vs 279 N), lower displacement at failure ( $p = .0003$ ; 0.436 mm vs 0.680 mm), and higher interface stiffness ( $p < .0001$ ; 1,641 N/mm vs 619 N/mm) than pull-out test. Failure load, stiffness, and secondary implant stability were significantly higher for longer compared with shorter healing periods, while displacement, tibia weight, and primary stability were not. Failure load and stiffness differed significantly for four healing times for the push-in but not pull-out test. Failure load was significantly correlated with secondary implant stability for both push-in ( $r = 0.66$ ) and pull-out ( $r = 0.48$ ) tests, but stiffness was significantly correlated with secondary stability only for the push-in test ( $r = 0.72$ ; pull-out test  $r = 0.40$ ).

### Conclusions

The push-in test appeared more sensitive than pull-out to changes in mechanical properties at bone-implant interfaces during healing in rabbit tibia model.

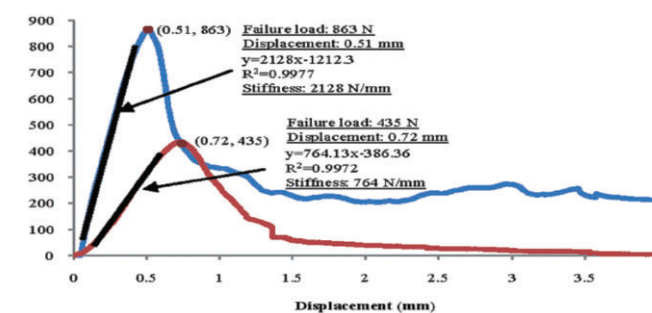


Fig. 1. Force-displacement graphs for both pull-out (red: left tibia) and push-in (blue: right tibia) tests for rabbit number 12 from the 12-week healing group.

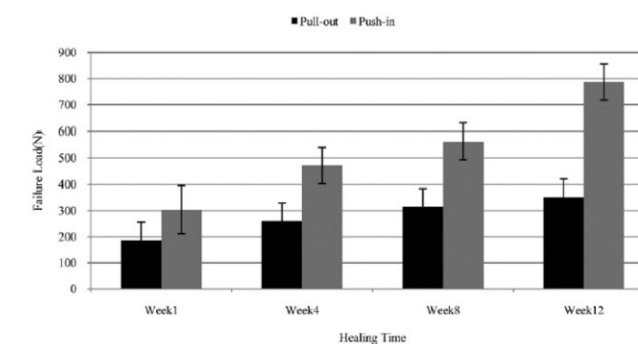


Fig. 2. Failure load measured by pull-out (black) and push-in (grey) tests, with the different healing periods (1- to 12-week).

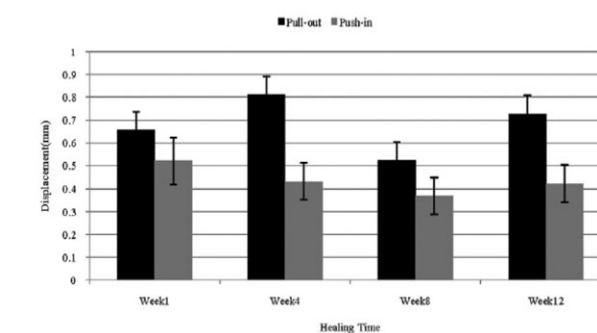


Fig. 3. Displacement measured at the failure of the bone-implant interface under pull-out (black) and push-in (grey) tests, with the different healing periods (1- to 12-week).

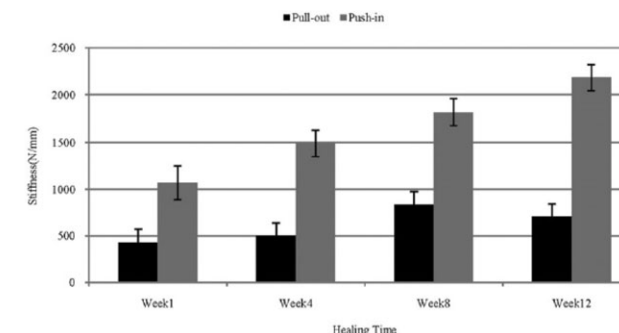


Fig. 4. Stiffness of the bone-implant interface measured by pull-out (black) and push-in (grey) tests, with the different healing periods (1- to 12-week).

# Quantitative Biomechanical Analysis of the Influence of the Cortical Bone and Implant Length on Primary Stability

Jongrak Hong, Young-Jun Lim, Sang-Oh Park  
Clin Oral Impl Res 2013; 23(10):1193-7

## Objective

The aim of the study was to investigate the influence of cortical bone and increasing implant fixture length on primary stability. Further investigation considered the correlation between the presence of cortical bone at the marginal bone and implant stability measured by insertion torque (IT) and resonance frequency analysis (RFA), as well as implant length, were determined.

## Materials & Methods

Two different types of polyurethane bone models were compared. (Group 1: with cortical and cancellous bone; Group 2: with cancellous bone only). A total of 60 external type implants ( $\phi$  4.1, Osstem, USII) with different lengths (7, 10, and 13 mm) were used. IT was recorded automatically by a computer which was connected to the Implant fixture installation device during the placement. RFA was conducted to quantify the primary implant stability quotient (ISQ). All two measurements were repeated 10 times for each group.

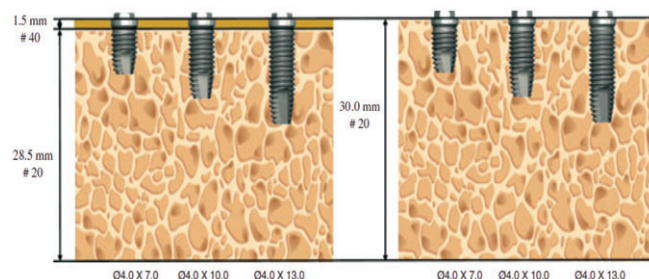


Fig. 1. Schematic drawing of this experiment.

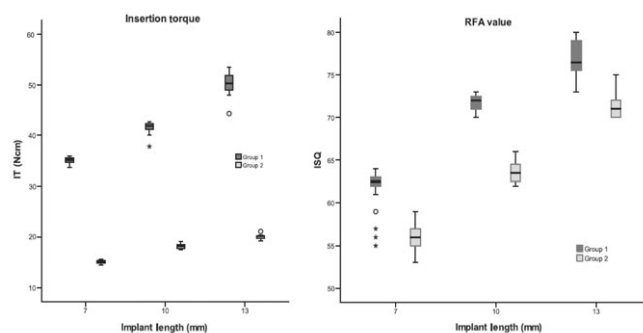


Fig. 2. Boxplots of maximum insertion torque(left) and ISQ values(right).

## Results

All these differences were statistically significant between the two groups ( $P < 0.001$ ) and intragroups ( $P < 0.001$ ). Upon comparing the IT, cortical bone appears to have a greater influence on implant stability than implant lengths, whereas the RFA value strongly affects implant length rather than the presence of the crestal cortical bone.

## Conclusions

The quantitative biomechanical evaluations clearly demonstrated that primary implant stability seems to be influenced by the presence of a cortical plate and total surface area of the implant fixture appears to be the decisive determinant for ISQ value.

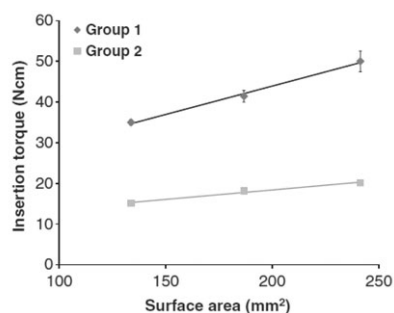


Fig. 3. Relationship between implant fixture surface area and insertion torque.

# Heat Transfer to the Implant-Bone Interface During Preparation of Zirconia/Alumina Complex Abutment

Jung-Bo Huh, Steven E. Eckert, Seok-Min Ko, Yong-Geun Choi  
Int J Oral Maxillofac Implants 2009;24:679-83

## Objective

Excessive heat at the implant-bone interface may compromise osseointegration. This study examined heat generated at the implant surface during preparation of zirconia/alumina complex abutment in vitro.

## Material & Methods

Sixty zirconia/alumina complex abutments (ZioCera, Osstem, Seoul, Korea) were randomized to twelve experiment groups. The abutments were connected to implant (USII, Osstem, Seoul, Korea) and were embedded in an acrylic-resin block in a 37°C water bath. Abutments were reduced horizontally 1mm height over a period of 1 minute with highspeed handpiece and polished for 30 seconds with lowspeed handpiece "with air/water coolant" and "without coolant." Temperatures were recorded via thermocouples at the cervical, middle, and apical part of the implant surface. The Mann-Whitney rank-sum test was used to assess the statistical significance of difference of temperature between with coolant and without coolant.

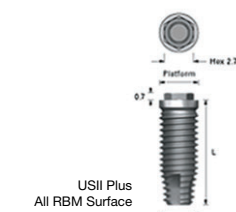


Fig. 1. USII Plus implant (Diameter:4.0mm, Length:13mm).



Fig. 2. ZioCera Abutment (Platform: regular, Height: 5.5mm, collar:5.0mm).

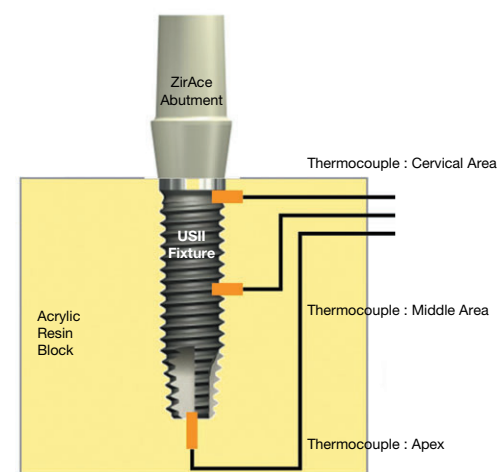


Fig. 3. Schematic of locations of three temperature sensors.

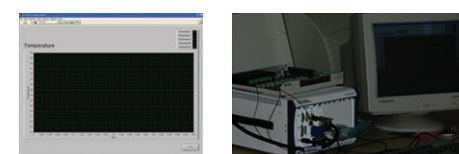


Fig. 4. Temperature monitoring system: LabView (National Instrument, Texas, US), PXI6259 (National Instrument, Texas, US).

## Results

1mm reduction with highspeed handpiece without coolant resulted in maximum temperature of 41.22°C at the cervical of implant. 3 of 4 temperatures more than 40°C were observed at the cervical part of implant with highspeed handpiece without coolant. Temperature difference between "with coolant" and "without coolant" during both lowspeed polishing and highspeed reduction was statistically significant at the cervix of implant ( $p = 0.009$ ). In contrast, temperature difference between "with coolant" and "without coolant" during both lowspeed polishing and highspeed reduction was not statistically significant at the middle and apical part of implant ( $p > .05$ ).

Table 1. Temperatures at each location of implant during preparation of five abutments using each handpiece type accompanied with coolant and without coolant

Experiment Group	Handpiece type	Coolant	Location	Abutment 1 (°C)	Abutment 2 (°C)	Abutment 3 (°C)	Abutment 4 (°C)	Abutment 5 (°C)
1	High	Yes	Cervical	38.58	37.50	38.90	37.80	38.58
2	High	Yes	Middle	37.80	37.50	37.02	36.69	37.21
3	High	Yes	Apical	37.50	37.39	37.02	36.33	37.21
4	High	No	Cervical	41.22	40.22	38.99	40.10	39.58
5	High	No	Middle	37.15	38.00	36.98	37.55	37.12
6	High	No	Apical	37.15	37.69	36.98	37.50	37.01
7	Low	Yes	Cervical	37.55	37.56	37.89	37.11	37.00
8	Low	Yes	Middle	37.01	37.00	36.98	37.45	37.69
9	Low	Yes	Apical	37.01	36.99	36.98	37.45	37.69
10	Low	No	Cervical	39.33	38.52	39.12	38.20	40.01
11	Low	No	Middle	37.08	37.96	37.45	37.45	37.23
12	Low	No	Apical	37.08	37.93	37.40	37.10	37.00

Table 2. Mean temperature and statistical significance of temperature difference for Zirconia/Alumina Complex abutment with highspeed contouring

Location	Coolant	Mean temperature ± SD	Statistical significance (p-value)
Cervical	Yes	38.27 ± 0.59	0.009
	No	40.02 ± 0.83	
Middle	Yes	37.24 ± 0.43	0.754
	No	37.36 ± 0.42	
Apical	Yes	37.09 ± 0.46	0.834
	No	37.27 ± 0.31	

Table 3. Mean temperature and statistical significance of temperature difference for Zirconia/Alumina Complex abutment with lowspeed polishing

Location	Coolant	Mean temperature ± SD	Statistical significance (p-value)
Cervical	Yes	37.42 ± 0.36	0.009
	No	39.04 ± 0.71	
Middle	Yes	37.23 ± 0.33	0.245
	No	37.43 ± 0.33	
Apical	Yes	37.22 ± 0.33	0.465
	No	37.30 ± 0.38	

## Conclusions

Preparation of zirconia/alumina complex abutment caused an increase in temperature within the implant but this temperature increase did not reach critical levels described in implant literature.

# Fatigue Fracture of Different Dental Implant System Under Cyclic Loading

Won-Ju Park, In-Ho Cho  
J Kor Acad Prosthodont 2009;47:424-34

## Objective

Implant has weak mechanical properties against lateral loading compared to vertical occlusal loading, and therefore, stress analysis of implant fixture depending on its material and geometric features is needed.

## Materials & Methods

Total 28 of external hexed implants were divided into 7 of 4 groups; Group A (3i, FULL OSSEOTITE Implant), Group B (Nobelbiocare, Bra nemark System Mk III Groovy RP), Group C (Neobiotec, SinusQuick™ EB), Group D (Osstem, USII). The type III gold alloy prostheses were fabricated using adequate UCLA gold abutments. Fixture, abutment screw, and abutment were connected and cross-sectioned vertically. Hardness test was conducted using MXT- $\alpha$ . For fatigue fracture test, with MTS 810, the specimens were loaded to the extent of 60 - 600 N until fracture occurred. The fracture pattern of abutment screw and fixture was observed under scanning electron microscope. A comparative study of stress distribution and fracture area of abutment screw and fixture was carried out through finite element analysis.

Group	Manufacturer	Implant	Type	Abutment	Abut. screw
A	3i Implant Innovations Inc., FL, USA	FULL OSSEOTITE	External	UCLA Gold Standard ZHTM	Gold 99.9%
B	Nobel biocare AB, Göteborg, Sweden	Mk III Groovy RP	External	Gold Adapt Engaging Branemark System RP	Titanium
C	Neobiotec Co., Ltd., Seoul, Korea	SinusQuick™ EB	External	Gold UCLA Gold Abutment regular/single	Titanium
D	Osstem, Seoul, Korea	USII	External	US UCLA Gold Abutment	Ebony Gold

## Results

- In Vicker's hardness test of abutment screw, the highest value was measured in group A and lowest value was measured in group D.
- In all implant groups, implant fixture fractures occurred mainly at the 3 - 4th fixture thread valley where tensile stress was concentrated. When the fatigue life was compared, significant difference was found between the group A, B, C and D ( $p < .05$ ).
- The fracture patterns of group B and group D showed complex failure type, a fracture behavior including transverse and longitudinal failure patterns in both fixture and abutment screw. In Group A and C, however, the transverse failure of fixture was only observed.
- The finite element analysis infers that a fatigue crack started at the fixture surface.

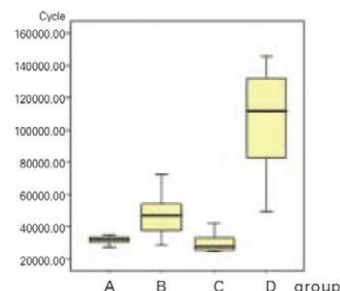


Fig. 1. Mean fatigue life of each implant.




Fig. 2. SEM picture of fractured surface of A, B, C and D implant.

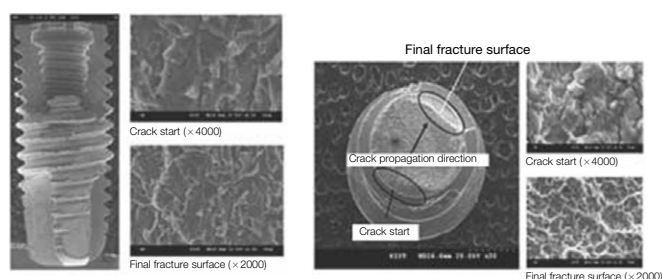


Fig. 3. SEM picture of fractured surface of B implant.

Fig. 4. SEM picture of fracture surface of B abutment screw.

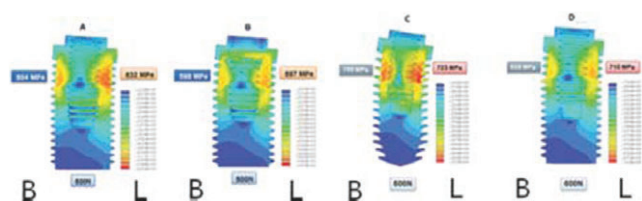


Fig. 5. Stress distribution of implant under 600 N loading in 30 angle.

## Conclusions

The maximum tensile stress was found in the implant fixture at the level of cortical bone. The fatigue fracture occurred when the dead space of implant fixture coincides with jig surface where the maximum tensile stress was generated. To increase implant durability, prevention of surrounding bone resorption is important. However, if the bone resorption progresses to the level of dead space, the frequency of implant fracture would increase. Thus, proper management is needed.

## US System References

### Clinical Study

- Jong-Hwa Kim, Young-Kyun Kim, Ji-Hyun Bae. Retrospective clinical study on sinus bone graft and tapered-body implant placement. J Korean Assoc Oral Maxillofac Surg 2013;39:77-84
- Kwang Chung, Chul-Jung Oh, Ji-Won Ha, Min-Suk Kook, Hong-Ju Park, Hee-Kyun Oh, Su-Gwan Kim, Young-Kyun Kim, Woo-Cheol Kim. A multicenter clinical study of installed USII Plus / GSII Osstem implants after bone graft. Korean Dental Association. 2012;50(12):743-54
- Ji-A Moon, Min-Sung Cho, Seung-Gon Jung, Min-Suk Kook, Hong-Ju Park, Hee-Kyun Oh. Retrospective Study of Bone Resorption after Maxillary Sinus Bone Graft. J Kor Dent Sci. 2011;4(2):59-66
- Sang-Woon Moon, Young-Kyun Kim. Analysis of Prognostic Factors after a Variety of Osstem Implant Installation. Implantology 2011;15(2):170-9
- Sun-Keun Kim, Jee-Hwan Kim, Keun-Woo Lee, Kyoo-Sung Cho, Dong-Hoo Han. Success Rate and Marginal Bone Loss of Osstem USII plus Implants; Short term Clinical Study. J Korean Acad Prosthodont 2011;49(3):206-13
- Su-Won Park, Soo-Mi Jang, Byoung-Hwan Choi, Han-Na Son, Bong-chan Park, Chang-Hwan Kim, Jang-Ho Son, IeI-Yong Sung, Ji-Ho Lee, Yeong-Cheol Cho. The Study of Bone Density Assessment on Dental Implant Sites. J Korean Assoc Oral Maxillofac Surg 2010;36(5):417-22
- Young-Kyun Kim, Pil-Young Yun, Su-Gwan Kim, Bum-Soo Kim, Joo L Ong. Evaluation of Sinus Bone Resorption and Marginal Bone Loss after Sinus Bone Grafting and Implant Placement. Oral Surg Oral Med Oral Pathol Oral Radiol Endod 2009;107:e21-8
- Bum-Soo Kim, Young-Kyun Kim, Pil-Young Yun, Yang-Jin Yi, Hyo-Jeong Lee, Su-Gwan Kim, Jun-Sik Son. Evaluation of Peri-implant Tissue Response according to the Presence of Keratinized Mucosa. Oral Surg Oral Med Oral Pathol Oral Radiol Endod 2009;107:e24-8
- Young-Dai Song, Sang-Ho Jun, Jong-Jin Kwon. Correlation Between Bone Quality Evaluated by Cone-Beam Computerized Tomography and Implant Primary Stability. Int J Oral Maxillofac Implants 2009;24(1):59-64
- Mi-A Kwon, Yong-Deok Kim, Chang-Mo Jeong, Ju-Youn Lee. Clinical and Radiographic Evaluation of Implants with Dual-microthread: 1-year Study. J Korean Acad Periodontol 2009;39(1):27-36
- Jang-Ho Son, Byung-hwan Choi, Soo-Won Park, Yeong-Cheol Cho, IeI-Yong Sung, Ji-Ho Lee, Ki-Jung Byun. Bone Density and Histomorphometry Assessment of Dental Implant Using Computerized Tomography. J Korean Assoc Maxillofac Plast Reconstr Surg 2009;31(2):137-46
- Hyun-Joo Kim, Woon-Jung Noh, Seung-II Song, Sok-Min Ko. Implant Replacement Utilizing Zirconia Abutment in Esthetic Zone. J Korean Implantology(KAOMI) 2009;13(2):16-24
- Seong-Yeon Lee, Young-Kyun Kim, Pil-Young Yun, Yang-jin Yi, In-Sung Yeo, Hyo-Jung Lee, Ji-Young Lee. Prospective Clinical Study of Short Implant. Scientific Poster, 4th Congress of the ICOI Korea 2009
- Moo-Gyung Sung. User Guide of Osstem Implant Systems. Scientific Oral, The 50th Anniversary of KAP, International Prosthodontic Congress & The 6th Biennial Meeting of Asian Academy of Prosthodontics (AAP) 2009
- Sung-Moon Back, Min-Suk Oh, Su-Kwan Kim. A Retrospective Study on the Clinical Success Rate of Osstem Implant. Key Engineering Materials 2008;361-3:1331-4
- Hong-Ju Park, Min-Suk Kook, Su-Gwan Kim, Young-Kyun Kim, Yong-Seok Cho, Gab-Lim Choi, Young-Hak Oh, Hee-Kyun Oh. Multicenter Retrospective Study of Immediate Two Different RBM Surfaced Implant Systems after Extraction. J Korean Assoc Maxillofac Plast Reconstr Surg 2008;30(3):258-65
- Min-Suk Kook, Hong-Ju Park, Su-Gwan Kim, Young-Kyun Kim, Yong-Seok Cho, Gab-Lim Choi, Young-Hak Oh, Hee-Kyun Oh. A Retrospective Multicenter Clinical Study of Installed USII / SSII Implants after Maxillary Sinus Floor Elevation. J Kor Oral Maxillofac Surg 2008;34:341-9
- Young-Kyun Kim, Pil-Young Yun, Jae-Hyung Im. Clinical Retrospective Study of Sinus Bone Graft and Implant Placement. J Korean Assoc Maxillofac Plast Reconstr Surg 2008;30(3):294-302
- Se-II Ki, Min-Gi Yu, Young-Joon Kim, Min-Suk Kook, Hong-Ju Park, Uttom Kumar Shet, Hee-Kyun Oh. A Retrospective Evaluation of Implant Installation with Maxillary Sinus Augmentation by Lateral Window Technique. J Korean Assoc Maxillofac Plast Reconstr Surg 2008;30(5):457-64
- Young-Kyun Kim, Pil-Young Yun, Min-Jung Kwon. Short term Retrospective Clinical Study on GSII, SSIII, USIII. J Korean Implantology (KAOMI) 2008;12(2):12-22
- Kang-Woo Kim, Jae-Kwan Lee, Heung-Sik Um, Beom-Seok Chang. Soft-tissue Management for Primary Closure in Immediate Implant Placement. J Korean Acad Periodontol 2008;38(2):253-62
- Bum-Soo Kim, Young-Kyun Kim, Pil-Young Yun, Yang-Jin Lee. Clinical Evaluation of Sinus Bone Graft Using Allograft and Xenograft. Scientific Poster, 17th Congress of EAO 2008
- Seo-Yoon Kim, Su-Gwan Kim, Hak-Kyun Kim. A Comparison between the Survival Rate of RBM surface implants and Acid-etched surface implants : A prospective 1-year Clinical Study. Scientific Poster, J Kor Oral Maxillofac Surg 2008; 34 (Suppl)

## US System References

24. Uttom Kumar Shet, Min-Suk Kook, Hong-Ju Park, Hee-Kyun Oh. Comparison of Bone Resorption Between Autogenous Bone Graft and Distraction Osteogenesis with Others Treatment Outcome. Scientific Poster, J Kor Oral Maxillofac Surg 2008; 34 (Suppl)
25. Su-Gwan Kim, Chul-Min Park, Young-Kyun Kim, Hee-Kyun Oh, Gab-Lim Choi, Young-Hak Oh. Multicenter Retrospective Clinical Study of Osstem USII Implant System in Type IV Bone. J Korean Implantology(KAOMI) 2007;11(3):22-9
26. Su-Gwan Kim, Min-Suk Oh, Young-Kyun Kim, Hee-Kyun Oh, Gab-Lim Choi, Young-Hak Oh. Multicenter Retrospective Clinical Study of Osstem USII Implant System in Complete Edentulous Patients. J Korean Implantology(KAOMI) 2007;11(3):12-21
27. Young-Kyun Kim. Inferior Alveolar Nerve Repositioning and Implant Placement: Case Reports. J Korean Implantology(KAOMI) 2007;11(2):42-50
28. Min-Seok Oh, Su-Gwan Kim, Hak-Kyun Kim, Seong-Yong Moon. Restoration of the Mandibular Overdenture Using Osstem Implants. Scientific Poster, 2nd Congress of the ICOI Korea 2007
29. Seok-Min Ko, Jeong-Keun Lee, Steven E. Eckert, Yong-Geun Choi. Retrospective Multicenter Cohort Study of the Clinical Performance of 2-stage Implants in South Korean Populations. Int J Oral & Maxillofac Implants 2006;21(5):785-8
30. Young-Kyun Kim, Pil-Young Yun, Dae-Il Son, Bum-Soo Kim, Jung-Won Hwang. Analysis of Clinical Application of Osstem (Korea) Implant System for 6 Years. J Korean Implantology(KAOMI) 2006;10(1):56-65
31. Ju-Rim Sun, Su-Gwan Kim, Hee-Yeon Choi, Jong-Woon Kim, Ho-Bin Lee, Jung-Yeop Park, No-Seung Park, Sang-Yeol Kim, Su-Kwon Kim, Ki-Pyo No, Young-Hoon Won. USII Implantation Using SimPlant Software in a Maxillary Edentulous Patient; A Case Report. J Korean Implantology(KAOMI) 2006;10(3):28-37
32. Sun-Hee Oh, Taek-Ga Kwon, Young-Kyun Kim, Jung-Won Hwang. Retrospective Study of Osstem Dental Implants; Clinical and Radiographic Results of 2.5 Years. Scientific Poster, 15th Congress of EAO 2006
33. Jin-Hwan Kim, Dong-Uk Jung. Vertical Ridge Augmentation and Implant Placement in Severe Bone Loss Area with Autogenous Bone and Bovine Bone. Scientific Poster, 1st Congress of the ICOI Korea 2006
34. Young-Kyun Kim, Jung-Won Hwang, Pil-Young Yun, Su-Gwan Kim, Chae-Heon Chung, Yong-Gun Choi, Sung-Il Song. Multicentric Prospective Clinical Study of Korean Implant System: Early Stability Measured by Periotest. J Korean Dent Assoc 2004;42(12): 873-81
35. Ki-Yoon Nam, Beon-Seok Chang, Heung-Sik Um. Retrospective Clinical Study of Domestic Dental Implant Success Rates. J Korean Acad Periodontol 2003;33(1):37-47
36. Jai-Bong Lee, Young-Soo Wang, Kwang-Ho Shin, Byung-Nam Hwang. Retrospective Multicenter Study of Osstem Endosseous Dental Implant. J Korean Dent Assoc 2000;38(6): 558-66

## Pre-Clinical Study Biology

1. Hong-Young Choi, Jae-June Park, In-Hee Cho, Tae-Kwan Eom. The Effects of Surface Roughness on the Sandblasted with Large Grit Alumina and Acid Etched Surface Treatment: In Vivo Evaluation. Scientific Poster, 20th Congress of EAO 2011
2. Min-Suk Kook, Seung-Gon Jung, Kyung-Mi Shim, Seong-Soo Kang, Hong-Ju Park, Sun-Youl Ryu, Hee-Kyun Oh. The Effect of Platelet Rich Plasma in Bone Formation on Implant Installation in the Tibia of Beagle Dogs. J Korean Assoc Oral Maxillofac Surg 2010;36:71-7
3. Jee-Hyun Park, Sun-Jung Hwang, Myung-Jin Kim. Effect of rhPDGF-BB and rhBMP-2 on Osseointegration of Titanium Implants at Periimplant Bone Defects Grafted with Hydroxyapatite: Micro-CT and Histologic Analysis. J Korean Assoc Maxillofac Plast Reconstr Surg 2009;31(6):461-8
4. Ji-Su Oh, Su-Gwan Kim, Sung-Chul Lim, Joo L. Ong. A Comparative Study of Two Noninvasive Techniques to Evaluate Implant Stability: Periotest and Osstell Mentor. Oral Surg Oral Med Oral Pathol Oral Radiol Endod 2009;107:513-8
5. Hong-Cheol Yoon, Jung-Yoo Choi, Ui-Won Jung, Eun-Kyung Bae, Seong-Ho Choi, Kyoo-Sung Cho, Ho-Yong Lee, Chong-Kwan Kim, June-Sung Shim. Effects of Different Depths of Gap on Healing of Surgically Created Coronal Defects around Implants in Dogs: A Pilot Study. J Periodontol 2008;79(2):355-61
6. Seong-Yong Moon, Su-Gwan Kim, Sung-Chul Lim, Joo L. Ong. Histologic and Histomorphometric Evaluation of Early and Immediately Loaded Implants in the Dog Mandible. J Biomed Mater Res 2008;86A:1122-7
7. Jeong-Wan Ha, Su-Gwan Kim. Histomorphometric Analysis of an Immediate Non-functional Loaded Implant in Dogs. J Korean Assoc Oral Maxillofac Surg 2008;34:90-4
8. Jin-Yong Cho, Young-Jun Kim, Min-Gi Yu, Min-Suk Kook, Hee-Kyun Oh, Hong-Ju Park. The Effect of Surface Treatment of the Cervical Area of Implant on Bone Regeneration in Mini-pig. J Korean Assoc Oral Maxillofac Surg 2008;34:285-92
9. Soo-Young Bae, Su-Kyoung Kim, Eun-Jung Kang, Young-Bae An, Gyu-Sub Eom, Tae-Gwan Eom. The Effect of Hydroxyapatite-blasted Titanium Surface Roughness on Osteoblast-like Cell Line MG-63. Scientific Poster, Meeting of the Korean Society for Biomaterials 2008
10. Jae-Wan Park, Min-Suk Kook, Hong-Ju Park, Uttom Kumar Shet, Choong-Ho Choi, Suk-Jin Hong, Hee-Kyun Oh. Comparative Study of Removal Effect on Artificial Plaque from RBM Treated Implant. J Korean Assoc Maxillofac Plast Reconstr Surg 2007;29(4):309-20
11. Se-Hoon Kahm, Yong-Chul Bae, Sung-Eun Yang, Chang-Hyen Kim, Je-Uk Park. Histomorphometric Analysis of Different Type Immediate Loaded Implants in Human. Scientific Poster, 16th Congress of EAO 2007
12. Cheong-Hwan Shim, Yu-Jin Jee, Hyun-Chul Song. Expression of Osseointegration-related Genes around Titanium Implant: BMP2, BMP4. J Korean Assoc Maxillofac Plast Reconstr Surg 2005;27(4):307-14
13. Who-Suk Hong, Tae-Hee Kim, Seong-Hee Ryu, Min-Suk Kook, Hong-Ju Park, Hee-Kyun Oh. Comparative Study of Osseointegration of 4 Different Surfaced Implants in the Tibia of Dogs. J Korean Assoc Oral Maxillofac Surg 2005;31:46-54
14. Su-Gwan Kim, Cheung-Yeoul Park, Sun-Sik Park, Myung-Duck Kim, Tae-Gwan Eom. Surface Properties of Endosseous Dental Implants after Nd:YAG and CO2 Laser Treatment at Various Energies. Scientific Poster, 20th Congress of AO 2005
15. Jae-Woo Kwak, Tae-Hee Kim, Hong-Ju Park, Hee-Kyun Oh. Effect of Implant Surface Characteristics on Osseointegration in the Ilium of Dogs. J Korean Assoc Maxillofac Plast Reconstr Surg 2004;36(6):531-41
16. Tae-Il Kim, Tae-Gwan Eom, Tae-Hee Byun, Kyu-Ok Choi, Jae-Ho Kim. Elemental Analysis of the Surface Residues on Dental Implants. Biomaterials Research 2003;7(4):254-9

## US System References

### Pre-Clinical Study Biomechanics

1. Jongrak Hong, Young-Jun Lim, Sang-Oh Park. Quantitative biomechanical analysis of the influence of the cortical bone and implant length on primary stability. *Clin Oral Impl Res* 2013; 23(10): 1193-7
2. Wook-Jin Seong, Shahrzad Grami, Soo-Cheol Jeong, Heather J. Conrad, James S. Hodges. Comparison of Push-in versus Pull-out Tests on Bone-Implant Interfaces of Rabbit Tibia Dental Implant Healing Model. *Clin Implant Dent Res* 2013;15(3):460-9
3. Ki-Seong Kim, Young-Jun Lim, Myung-Joo Kim, Ho-Beom Kwon, Jae-Ho Yang, Jai-Bong Lee, Soon-Ho Yim. Variation in the Total Lengths of Abutment/Implant Assemblies Generated with a Function of Applied Tightening Torque in External and Internal Implant-Abutment Connection. *Clin Oral Impl Res* 2011;22:834-9
4. Won-Ju Park, In-Ho Cho. Fatigue Fracture of Different Dental Implant System under Cyclic Loading. *J Kor Acad Prosthodont* 2009;47:424-34
5. Sung-Ae Shin, Chang-Seop Kim, Wook Cho, Chang-Mo Jeong, Young-Chan Jeon, Ji-Hoon Yoon. Mechanical Strength of Zirconia Abutment in Implant Restoration. *J Korean Acad Stomatog Func Occ.* 2009;25(4):347-58
6. Jung-Bo Huh, Steven E. Eckert, Seok-Min Ko, Yong-Geun Choi. Heat Transfer to the Implant-Bone Interface during Preparation of Zirconia/Alumina Complex Abutment. *Int J Oral Maxillofac Implants* 2009;24(4):679-83
7. Ju-Hee Park, Young-Jun Lim, Myung-Joo Kim, Ho-Beom Kwon. The Effect of Various Thread Designs on the Initial Stability of Taper Implants. *J Adv. Prosthodont* 2009;1:19-25
8. Tae-Gwan Eom, Seung-Woo Suh, Gyeo-Rok Jeon, Jung-Wook Shin, Chang-Mo Jeong. Effect of Tightening Torque on Abutment-Fixture Joint Stability using 3-Dimensional Finite Element Analysis. *J Kor Acad Prosthodont* 2009;47(2):125-35
9. Myung-Seok Kim, Seong-Joo Heo, Jai-Young Koak, Sung-Kyun Kim. Strains of Abutment and Bones on Implant Overdentures. *J Kor Acad Prosthodont* 2009;47(2):222-31
10. Mi-Soon Lee, Kyu-Won Suh, Jae-Jun Ryu. Screw Joint Stability under Cyclic Loading of Zirconia Implant Abutments. *J Kor Acad Prosthodont* 2009;47(2):164-73
11. Il-Song Park, Sang-Yong Won, Tae-Sung Bae, Kwang-Yeob Song, Charn-Woon Park, Tae-Gwan Eom, Chang-Mo Jeong. Fatigue Characteristics of Five Types of Implant-Abutment Joint Designs. *Met. Mater. Int.* 2008;14(2):133-8
12. Hyon-Mo Shin, Chang-Mo Jeong, Young-Chan Jeon, Mi-Jeong Yun, Ji-Hoon Yoon. Influence of Tightening Torque on Implant-Abutment Screw Joint Stability. *J Kor Acad Prosthodont* 2008;46(4):396-408
13. Jae-Kyoung Park, Chang-Mo Jeong, Young-Chan Jeon, Ji-Hoon Yoon. Influence of Tungsten Carbide/Carbon Coating of Implant-Abutment Screw on Screw Loosening. *J Kor Acad Prosthodont* 2008;46(2):137-47
14. Tae-Sik Lee, Jung-Suk Han, Jae-Ho Yang, Jae-Bong Lee, Sung-Hun Kim. The Assessment of Abutment Screw Stability Between the External and Internal Hexagonal Joint under Cyclic Loading. *J Kor Acad Prosthodont* 2008;46(6):561-8
15. Jung-Bo Huh, Sok-Min Ko. The Comparative Study of Thermal Inductive Effect Between Internal Connection and External Connection Implant in Abutment Preparation. *J Kor Acad Prosthodont* 2007;45(1):60-70
16. Dae-Woong Kang, Sang-Wan Shin, Hyun Jung Jo, Sung-Hun Kim. The Effect of Various Designs of Dental Implant Fixtures on Their Initial Stability. *J Korean Implantology(KAOMI)* 2007;11(2):32-45
17. In-Ho Kang, Myung-Joo Kim, Young-Jun Lim, Chang-Whe Kim. The Effect of Autoclave Sterilization and Reuse of SmartpegTM, on the Implant Stability Quotient (ISQ) Measurement. *J Kor Acad Prosthodont* 2007;45(5):644-52
18. Si-Yeob Kim, Byung-kook Kim, Jin-Ho Heo, Ju-Youn Lee, Chang-Mo Jeong, Yong-Deok Kim. Evaluation of Stability of Double Threaded Implant-Emphasis on Initial Stability Using Osstell MentorTM; Part I. *J Kor Acad Stomatog Func Occlusion* 2007;23(4):327-36
19. Tae-Sik Lee, Jung-Suk Han, Jae-Ho Yang, Jae-Bong Lee, Sung-Hun Kim. An Influence of Abutment Materials on a Screw-Loosening after Cyclic Loading. *J Kor Acad Prosthodont* 2007;45(2):240-9
20. Ahran Pae, Kyung-A Jeon, Myung-Rae Kim, Sung-Hun Kim. Comparative Study on The Fracture Strength of Metal-Ceramic Versus Composite Resin-Veneered Metal Crowns in Cement-Retained Implant-Supported Crowns under Vertical Compressive Load. *J Kor Acad Prosthodont* 2007;45(3):295-302
21. Sok-Min Ko. The Accuracy of Impression Technique using the New Impression Coping. *Scientific Oral, 12th International College of Prosthodontists Meeting*
22. Chae-Heon Chung. Detorque Force of TiN-coating Abutment Screw with Various Coating Thickness After Repeated Closing and Opening. *Scientific Oral, 12th International College of Prosthodontists Meeting*
23. Min-Gun Kim, Ji-Hun Lee, Dong-Yeol Kim. Simulation of Corrosion Fatigue Life on the Dental Implant. *Scientific Oral, Kor Society of Mechanical Engineers Conference, 2007*
24. Gap-Yong Oh, Sung-Hwa Park, Seok-Gyu Kim. Influence of Implant Fixture Design on Implant Primary Stability. *J Kor Acad Prosthodont* 2006;45(1):98-106
25. Jin-Uk Choi, Chang-Mo Jeong, Young-Chan Jeon, Jang-Seop Lim, Hee-Chan Jeong, Tae-Gwan Eom. Influence of Tungsten Carbide/Carbon on the Preload of Implant Abutment Screws. *J Kor Acad Prosthodont* 2006;44(2):229-42
26. Ki-Duk Park, Sang-Un Han, Hong-Seo Yang, Ju-Seok Kim. Three-Dimensional Finite Analysis of Functional Stresses in Varied Width of Crestal Bone, Implant Diameter and Buccal off Position. *Scientific Poster, 15th Congress of EAO 2006*
27. Yong-Suk Cho, Chul-Hyun Jeong, Tae-Soo Kim, Dong-Hoon Jang, Tae-Gwan Eom. Temperature Measurement During Implant-Site Preparation. *Scientific Poster, 15th Congress of EAO 2006*
28. Ji-Hoon Yoon, Sung-Geun Lee, Chang-Mo Jeong, Tae-Gwan Eom. The Study of Dynamic Behaviour about Implant System with WC/C Coating. *Scientific Poster, 15th Congress of EAO 2006*
29. Chun-Yeo Ha, Chang-whe Kim, Young-Jun Lim, Kyung-Soo Jang. The Effect of Internal Implant-Abutment Connection and Diameter on Screw Loosening. *J Kor Acad Prosthodont* 2005;43(3):379-92
30. Jung Bo Huh, Sok Min Ko. Heat Transfer to the Implant Bone interface During Setting of Autopolymerizing Acrylic Resin Applied to Impression Copings for Implant Impression. *J Korean Implantology(KAOMI)* 2005;9(2):44-9
31. Kwang-Hoon Kim, Chang-Mo Jeong, Ji-Hoon Yoon, Ji-Yun Seong. Effect of Implant-Abutment Joint Design on Dynamic Fatigue Strength. *Scientific Poster, 20th Congress of AO 2005*
32. Tae-Gwan Eom, Chang-Mo Jeong, Kwang-Hoon Kim. The Effect of Tightening Torque on Reliability of Joint Stability. *Scientific Poster, 14th Congress of EAO 2005*
33. Ji-Hoon Yoon, Chang-Mo Jeong, Tae-Gwan Eom, Mi-Hyun Cheon. Effect Joint Design on Static and Dynamic Strength. *Scientific Poster, 14th Congress of EAO 2005*
34. Tae-Hee Byun, Kwang-Hoon Kim. Study on the Adaptation to the Investment Water-Powder Ratio by the Abutment and Casting Crown. *Scientific Poster, Kor Dent Technician Associate 2005 Conference*
35. Byung-Gi Cho, Jae-Ho Ryu. Study of Possibility Direct Casting on Titanium Abutment. *Scientific Poster, Kor Dent Technician Associate 2005 Conference*
36. Byung-Soo Bae, Jae-Ho Ryu. Investigation of the Resin Adhesion and Task Convenience for Surface Shape. *Scientific Poster, Kor Dent Technician Associate 2005 Conference*
37. Su-Gwan Kim, T.H. Kang, Kyu-Ok Choi, Tae-Hee Byun, Tae-Gwan Eom, Myung-Duk Kim. Finite Element Stress Analysis according to Apical-Coronal Implant Position. *Scientific Poster, 19th Congress of AO 2004*
38. June-seok Lee, Yung-Soo Kim, Chang-Whe Kim, Jung-Suk Han. Wave Analysis of Implant Screw Loosening using an Air Cylindrical Cyclic Loading Device. *J Prosthet Dent* 2002;88:402-8
39. Yong-Tae Jeong, Chae-Heon Chung, Heung-Tae Lee. Screw Joint Stability according to Abutment Screw Materials. *J Kor Acad Prosthodont* 2001;39(3):297-305
40. Soel-Hee Choi, Young-Chan Jeon, Hee-Sung Hwang, Chang-Mo Jeong. Effect of Thin-gold Coating on the Preload and Removal Torque of Implant Prosthetic Retaining Screw. *J Korean Res Soc Dent Mater* 2000;27(2):117-27
41. Jae-Bong Lee. Preliminary Study on the Design of Screw Head for Rapid Fastening & Loosening. *J Kor Acad Family Medicine* 2000;2(2):26-31
42. Jae-Bong Lee. The Retrievalability of Cementation Type Implant Abutment by Surface Treatments and Types of Cements. *J Kor Acad Prosthodont* 1999;37(5):651-7
43. Jae-Bong Lee, Byung-Nam Hwang, Seung-Hyun Yoo, Chul-Jin Byun, Seok-Kyu Choi. The Comparative Study of Mechanical Stability Between Self Tapping Fixture and Double Threaded Fixture by 3-dimensional Finite Element Analysis. *J Kor Acad of General Dentistry* 1999;1(1):73-81

## Multicentric Retrospective Clinical Study on the Clinical Application of Mini Implant System

Young-Kyun Kim, In-Sung Yeo, Yang-Jin Yi, Un-Kyu Kim, Kyung-Nam Moon, Seung-Joon Jeon, Yong-Seok Cho, Pil-Young Yun  
J Korean Assoc Oral Maxillofac Surg 2010;36(4):325-30

### Objective

Mini-implant system is applicable to areas of narrow space and area requiring temporary loading support. The purpose of this study was to evaluate the clinical outcome of a mini-implant system as well as the application of mini-implant system in the dental clinical field.

### Materials & Methods

The patients who had been operated from Jan 2007 to Dec 2007 in the four dental facility including Seoul National University Bundang Hospital were enrolled. To evaluate the factors associated with the clinical outcome, the patients were classified according to gender, age, area of surgery, type of implant, diameter and length of the implant, and the purpose of the mini-implant system application.

Table 1. Patients' characteristics (n=69)

Variables	The number of cases (Implants)
Age (years)	
0-19	1 (4)
20-29	4 (4)
30-39	7 (11)
40-49	9 (25)
50-59	23 (36)
60-69	18 (51)
70-79	7 (19)
Gender	
Male	39 (73)
Female	30 (74)
Medical history	
Healthy	48(98)
Hypertension	10 (19)
Diabetes mellitus	8 (15)
Cerebrovascular attack history	2 (9)
Asthma 2 (6)	2 (6)
Alcoholism 2 (3)	2 (3)
Thyroid disease	1(5)
Smoking	
No	56 (123)
Yes	13 (24)
Results	
Success	66 (146)
Failure	3 (3)
Complications	
No	61 (141)
Osseointegration failure	3 (3)
Infection	3 (3)

### Results

From 147 implants, only three implants failed, one of them was for temporary loading. There were no serious surgical or prosthetic complications in this study.

### Conclusions

An analysis of the preliminary data revealed a satisfactory clinical outcome. However, more long-term evaluation of narrow ridge type as well as the patient's satisfaction on the use of a provisional type mini-implant system is needed.

## Clinical Research of Immediate Restoration Implant with Mini-Implants in Edentulous Space

Huang JS, Zhao JJ, Liu Q, Liu TT  
Hua Xi Kou Qiang Yi Xue Za Zhi. 2010 Aug;28(4):412-6

### Objective

The purpose of this study was to investigate the clinical effective of immediate restoration with Osstem MS mini-implant in the edentulous space of 5-6 mm.

### Materials & Methods

The sample consisted of 36 consecutively treated partially edentulous patients who had a total of 36 Osstem MS mini-implants, which were 2.5 mm or 3.0 mm in diameter and placed in 5-6 mm gap. The chair-side-made or laboratory-made provisional crowns for implants were fabricated at the time of fixtures placed. The final restorations were fabricated with gold alloy-fused-porcelain crown 3 to 5 months later. During the mean 21.3 months (12-37 months) follow-up time since fixtures placement, all implants were examined clinically and radiologically.

### Results

No implant failed before restoration. One implant led an adjacent tooth pulp necrosis after the implantation, but the natural tooth and implant were successfully retained by root canal therapy. 36 implants in 36 patients who were followed-up were successful and their aesthetic results were satisfactory.

### Conclusions

Immediate loaded implant with Osstem MS mini-implant has good clinical prosthetic effects in the edentulous space of 5-6 mm.

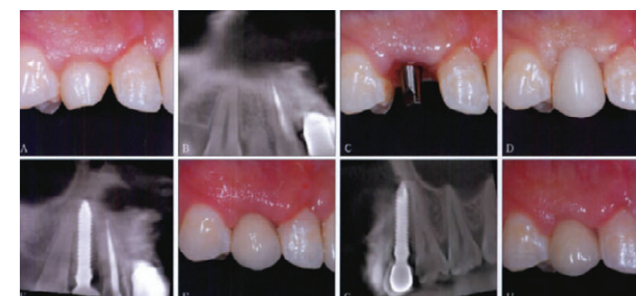


Fig. 1. Immediate restoration implant with mini-implant of case 1.

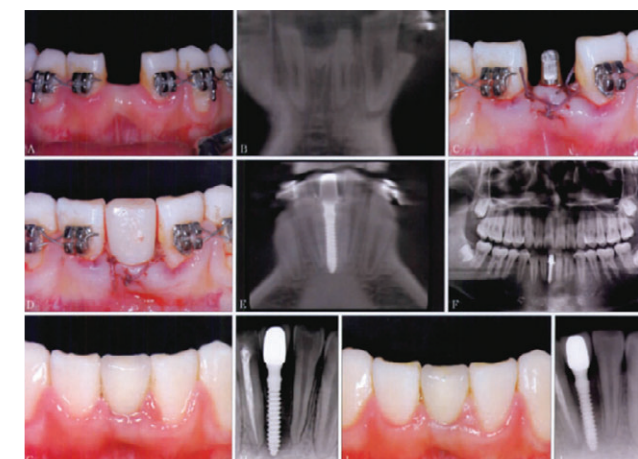


Fig. 2. Immediate restoration implant with mini-implant of case 2.

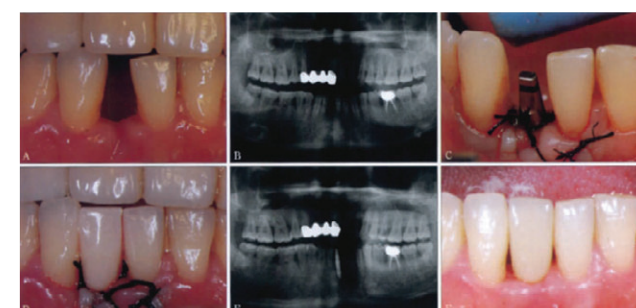


Fig. 3. Immediate restoration implant with mini-implant of case 3.

## MS System References

---

### Clinical Study

1. Kyo-Jin Ahn, Young-Kyun Kim, Pil-Young Yun, Yang-Jin Yi. Overdenture using MS Port mini-implants: A case report. J Korean Clinical Implant 2012;32(2):123-30
2. Yong-Jin Kim, Young-Jin Park, Kyung-Tae Park. Mandibular anterior single tooth replacement using the MS implant system. Scientific Poster, Osstem Meeting 2013
3. Young-Kyun Kim, In-Sung Yeo, Yang-Jin Yi, Un-Kyu Kim, Kyung-Nam Moon, Seung-Joon Jeon, Yong-Seok Cho, Pil-Young Yun. Multicentric Retrospective Clinical Study on the Clinical Application of Mini Implant System. J Korean Assoc Oral Maxillofac Surg 2010;36(4):325-30
4. Huang JS, Zhao JJ, Liu Q, Liu TT. Clinical Research of Immediate Restoration Implant with Mini-implants in Edentulous Space. Hua Xi Kou Qiang Yi Xue Za Zhi. 2010 Aug;28(4):412-6

The **“OSSTEM IMPLANT Research Project”** for the promotion of implantology may support clinical and laboratory research at the discretion of its research committee.

Further information concerning conditions can be obtained from the following address:

Clinical Oriented Research Team for Implantology  
Implant R&D Center of OSSTEM IMPLANT Co., Ltd.  
#38-44, Geoje 3-dong, Yeonje-gu, Busan, Korea. Zip. 611-801  
Tel. 82-70-7016-4745  
Fax. 82-70-4394-0404  
project@osstem.com  
<http://www.osstem.com>